

Short Note

First Genetic Record of a Strap-Toothed Beaked Whale (*Mesoplodon layardii*) Stranding in Chile

Sonia Español-Jiménez,¹ Constanza Abaud,² Camila Aceituno,³
Mario Alvarado-Rybak,^{3,4} Cintya Borroni,³ Gustavo Chiang,¹ Javier Díaz,³
Winfred Espejo,^{1,5} María Luisa Estay,^{1,6} Ana M. García-Cegarra,^{1,7,8}
Carlos González,³ Belén Gutierrez,^{1,9} Josefina Gutierrez,^{4,10} Daniel Henríquez,¹
Andrea Hirmas,^{1,3} Pamela Mejías,³ Constanza Meriño,^{1,3,11} Charity Molina,⁵
Camilo Naretto,² Florencia Olivares,^{1,12} Patricia Pereira,³ Diego Peñaloza,³
Betsy Pincheira,^{3,4} Nicolás Pinto,³ Omar Rojas,³ Carolina Sánchez,³
Barbara Toro,^{3,4,12} Frederick Toro,^{3,4,12,13} and Raimundo Undurraga²

¹Melimoyu Ecosystem Research Institute, Avenida Kennedy 5682, Santiago, Chile

E-mail: sespanol@fundacionmeri.cl

²Universidad Mayor, Facultad de Ciencias, Camino La Pirámide 5750, Huechuraba, Región Metropolitana, Chile

³Universidad Andrés Bello, Facultad de Ciencias de la Vida, Republica 440, Santiago, Región Metropolitana, Chile

⁴Asociación de Médicos Veterinarios de Fauna Silvestre (AMEVEFAS), Santiago, Región Metropolitana, Chile

⁵Universidad de Concepción, Facultad de Ciencias Veterinarias, Department of Animal Science,
Vicente Méndez 595, Chillán, Nuble, Chile

⁶Universidad de Chile, Facultad de Ciencias, Las Palmeras 3425, Ñuñoa, Región Metropolitana, Chile

⁷Centro de Investigación de Fauna Marina y Avistamiento de Cetáceos, Jesús Tejada 621, Mejillones, Antofagasta, Chile

⁸Universidad Santo Tomás, Facultad de Ciencias, Departamento de Ciencias Básicas,
Avenida Iquique 3991, Antofagasta, Chile

⁹Pontificia Universidad Católica de Chile, Facultad de Ciencias Biológicas,
Marcoleta 49, Santiago, Región Metropolitana, Chile

¹⁰Universidad Austral de Chile, Facultad de Ciencias Veterinarias, Programa de Magíster en Ciencias Mención
Salud Animal, Independencia 631, Valdivia, Los Ríos, Chile

¹¹Pontificia Universidad Católica de Valparaíso, Facultad de Ciencias del Mar y Geografía,
Escuela de Ciencias del Mar, Altamirano 1424, Valparaíso, Chile

¹²ONG Panthalassa, Red de Estudios de Vertebrados Marinos en Chile,

Avenida Toesca 2002, Apartment 611, Santiago, Región Metropolitana, Chile

¹³Universidad Santo Tomás, Facultad de Medicina Veterinaria y Recursos Naturales,
Escuela de Medicina Veterinaria, Avenida Limonares 190, Viña del Mar, Valparaíso, Chile

Of all the cetacean families, the Ziphiidae are one of the most enigmatic (MacLeod, 2018). They are the second most diverse family after the Delphinidae (Dalebout et al., 2002). They dive very deep for prolonged periods, spending little time at the surface between dives; and they live predominantly offshore in oceanic waters (MacLeod & D'Amico, 2006), which makes studying them more difficult and explains why they are so poorly understood (MacLeod, 2018). Most of the studies regarding ziphiids have been carried out on stranded individuals (Rosario-Delestre et al., 1999; Dalebout et al., 2002). Certain key features of the Ziphiidae, such as the location and shape of male tusks (MacLeod, 1998, 2018; MacLeod & Herman, 2007; Pitman, 2018), facilitate species identification, particularly

within the cryptic genus *Mesoplodon* (MacLeod, 2018); however, similarities among species and poor knowledge of body color patterns can lead to misidentification, especially in the case of female and juvenile specimens as body color patterns are to some extent unknown and are similar between females and juveniles (Pitman, 2018). In general, a molecular genetic analysis is considered the most reliable method for species identification (Kim et al., 2019).

The strap-toothed beaked whale (STW; *Mesoplodon layardii*) is classified in the International Union for Conservation of Nature's (IUCN) *Red List* as "Data Deficient" (Taylor et al., 2008). STW strandings have been registered in many countries: Argentina, Australia, Brazil,

the Falkland Islands, French Southern Territories, Heard Island and McDonald Islands, Namibia, New Zealand, South Africa, South Shetland Islands, and Uruguay (Taylor et al., 2008). Genetic sequencing has only been carried out on some of these strandings: only 16 partial sequences (including ours) from the Control Region gene of mitochondrial DNA could be obtained from GenBank, mainly from the Falkland Islands (eight) and New Zealand (four) (Dalebout et al., 1998, 2004; Otley et al., 2012).

Most STW strandings in Chile have been found in the southernmost area of the country (Venegas & Sielfeld, 1978; Sielfeld, 1979; Gibbons et al., 2000; International Whaling Commission [IWC], 2007; Figure 1), but these records contain several inconsistencies and data gaps. Reviewing the information available for these strandings, records 1 and 2 (Figure 1) could correspond to the same animal as they were registered in the same year and similar locations; however, given the lack of bibliographic evidence for record 1, it is impossible to know the complete details. A mandibular symphysis appears in two 1978 records: one found on the eastern mouth of the Strait of Magellan (which would relate it to the tooth found in 1978), and the other found in Cabo del Espíritu Santo. The original documentation of these records are no longer available. The record of the northernmost stranding occurred on 22 May 2007 in Constitución; it remains stored in the Museo de Historia Natural e Histórico in San Antonio, but there is no record of genetic validation of its identification. According to the local newspaper, this specimen was male, but the official report registered it as female (IWC, 2007). Given the sparse evidence of STW in Chilean waters, more accounts and observations

are needed to understand the range and habitat use of this species in this area. Herein, we document a recent STW stranding and provide the first genetic record of STW occurrence in Chilean Patagonia.

On 20 March 2019, near Caleta Tortel Bay (47° 50' 00" S, 73° 34' 00" W) in the Aysén region of Chile, a live STW was observed swimming with slow and aimless movements close to a little stone beach. Immediate rescue maneuvers began, performed by the Navy and personnel from the Chilean Fisheries and Aquaculture Service (SERNAPESCA) in Aysén. Several attempts to return the animal to the sea with zodiacs and scuba divers were made, but the animal repeatedly returned to the beach. While rescue maneuvers were being conducted, a second smaller individual of similar anatomical characteristics was sighted in the same area. This second individual was approached slowly in an inflatable boat to assess if it was injured, but it retreated to deeper waters. It remained in the area until the evening, after which it was not seen again. After 2 h of rescue attempts, the first STW died stranded on the beach (Figure 2).

This STW carcass was transported from the Caleta Tortel shore to the Colina Campus of the Universidad Andrés Bello School of Veterinary Medicine in Santiago for a full necropsy. The transport took 7 d in total, including a ferry ride. The carcass was moved in a freezer truck at -20°C. The necropsy was carried out 10 d after the stranding following protocols from the Stranding and Mass Mortality Committee of the Chilean Wildlife Veterinarian Association (Asociación de Médicos Veterinarios de Fauna Silvestre [AMEVEFAS], 2017) and the necropsy technique and tissue sampling from the European Cetacean Society (Barnett et al., 2018).

Skin samples were preserved for genetic analyses in a 100% ethanol solution at -20°C.

Record	Evidence	Year	Location	Reference
1	Skull	1968	Chabunco, Punta Arenas	Without reference
2	Photography	1968	17 km north of Punta Arenas	Venegas & Sielfeld, 1978
3	Right tooth (CE-4)	1978	Eastern exit of the Strait of Magellan	Venegas & Sielfeld, 1978
4	Mandibular symphysis	1978	Eastern exit of the Strait of Magellan	Venegas & Sielfeld, 1978
5	Skull (CE-25)	1979	Windhond Bay, Navarino Island	Sielfeld, 1979
6	Whole animal	2007	1 km north of Maule River, Constitución	IWC, 2007

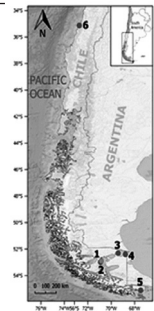


Figure 1. Location of all the stranding records of strap-toothed beaked whales (STWs; *Mesoplodon layardii*) in Chile reviewed in literature. The numbers in the figure correspond to those listed in the table. The GPS coordinates of the first five records are approximate according to the sites where the evidence was found. Only latitude was known for record 6, while longitude was estimated.




Figure 2. (A) Map of Caleta Tortel location; and photos of the stranded male STW in Caleta Tortel: (B) live animal and (C) color patterns observed on its ventral side.

DNA was extracted using the Phenol-Chloroform extraction method (modified from Sambrook et al., 1989; Aljanabi & Martinez, 1997). A 696 base pair fragment of the Control Region gene (GenBank Accession Number MN807948) was amplified by polymerase chain reaction (PCR) using light-strand primers tPro-whale Dlp-1.5 (5'-TCACCCAAAGCTGRAATTCTA-3'; Dalebout et al., 1998) and heavy-strand primers Dlp-8G (5'-GGAGTACTATGTCCTGTAACCA-3'; Dalebout et al., 2005). PCR products were observed in 1.5% agarose gel electrophoresis with SYBR Green® (Invitrogen, Carlsbad, CA, USA). PCR products were purified using a Wizard® clean-up kit (Promega, Madison, WI, USA) and sequenced using both PCR primers separately in an ABI 3100 DNA sequencer (Applied Biosystems, Foster City, CA, USA). Sequences were edited manually, and consensus sequences were blasted against the GenBank nucleotide data for species identification using BLAST (<https://blast.ncbi.nlm.nih.gov/Blast>).

To determine the phylogeography of the STW species in the Southern Hemisphere, the haplotype found in this beached STW specimen was compared to previously described haplotypes from the Falkland Islands and New Zealand strandings (Dalebout et al., 1998, 2004; Otley et al., 2012). A network of median-joining haplotypes of genealogical relationships was built using said sequences. This process provides information regarding the genetic structure of the species and its typical geographical distribution (Dalebout et al., 2004). Sequences were aligned using the

Clustal W algorithm implemented in *Geneious*, Version 11 (<https://www.geneious.com>; Kearse et al., 2012). Once aligned, the median-joining haplotype network analysis was carried out with *Network*, Version 4 software (Bandelt et al., 1999).

The results confirmed that the studied individual is an adult male *M. layardii*. As far as we can determine, this is the first specimen of this species confirmed by genetic analysis in Chile. The mitochondrial DNA Control Region gene analysis and its subsequent comparison with similar sequences in the GenBank database provided additional confirmation that the stranded animal was a STW (100% blast analysis query cover). Fifteen previously published sequences of the Control Region gene were obtained from this database (Australia = 2; the Falkland Islands = 8; New Zealand = 4; South Georgia = 1), with a size of 329 base pairs. The haplotype found in the Chilean ziphiid corresponded to the most common haplotype, which previously has been found in STWs in Australia, the Falkland Islands, New Zealand, and South Georgia (Figure 3).

The STW carcass condition was classified as a code 4 out of 5, and its decomposition state was between 2 and 3 out of 5 (Rowles et al., 2001). The exact weight could not be obtained, but given the characteristics of the crane used to move the carcass, it weighed at least 1,500 kg and was 5.21 m long (for morphometric details, see Table 1). The external examination showed several marks on the body surface with multiple lacerations in the mid-caudal area, ventral to the left pectoral fin, and in the

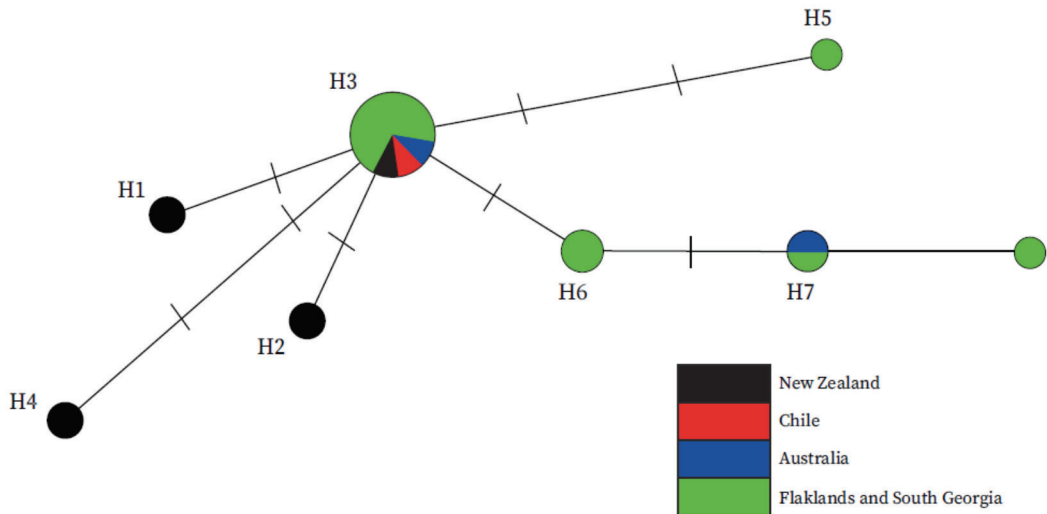


Figure 3. Network of median-joining haplotypes of genealogical relationships among the Control Region gene of mitochondrial DNA from STWs stranded in New Zealand, Chile, Australia, the Falkland Islands, and South Georgia. The length of the branches is proportional to the number of inferred mutational steps; this is indicated by a short gray line on the branches. The diameter of each circle is proportional to the number of individuals who share the same haplotype. The name of the haplotypes is indicated to the side of each circle.

Table 1. Morphometric measurements of the stranded strap-toothed beaked whale (STW; *Mesoplodon layardii*) near Caleta Tortel in March 2019

Characteristics measured	Length (m)	Characteristics measured	Length (m)
Total length	5.21	Tip of the snout to genital slit center	3.48
Length without fluke	4.85	Tip of the snout to anus	3.90
Tip of the snout to melon apex	0.39	Fluke midpoint to anus	1.25
Tip of the snout to oral commissure	0.44	Circumference of axillary region	2.86
Tip of the snout to center of an eye	0.84	Circumference in anterior insertion of dorsal fin	2.62
Tip of the snout to center of blowhole	0.77	Circumference in anal region	1.90
Tip of the snout to anterior insertion of pectoral fin	1.30	Dorsal fin height	0.32
Tip of the snout to posterior insertion of pectoral fin	3.26	Length of the left pectoral fin	0.50
Tip of the snout to tip of dorsal fin	3.65	Maximum width of left pectoral fin	0.19
Tip of the snout to umbilical zone	2.66	Fluke width	1.44

cervical area. Most of them were recent, most likely due to the stranding. A dorsoventral laceration was found in the rib zone measuring 28.9 cm long and 4.2 cm deep (Figure 4A). The fluke had a puncture wound (Figure 4B), and the penis was everted due to bloating of the inguinal area (Figure 4E). A hematoma was observed in the left thoracic area, 20 cm long and 4 cm wide (Figure 4C). From the caudal

to the left eye, there were four tooth scars, possibly from a cookiecutter shark (*Isistius* sp.) bite; and small abrasions were observed on the external sides of the mouth. Two teeth were erupted, presenting a complete fracture at the base prior to death, caused by epibionts found anchored in the fracture of the left medial tooth (Figure 4G). The outer edges of the rostrum presented smooth bilateral indentations

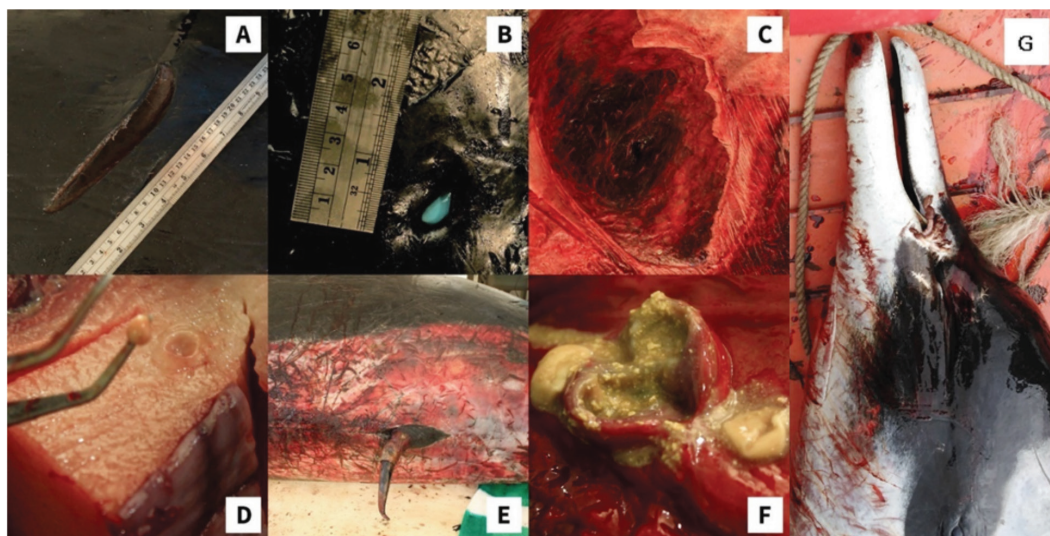


Figure 4. Main findings of the necropsy of the stranded STW near Caleta Tortel in 2019: (A) Large dorsoventral laceration in the rib zone, 4 cm deep; (B) perforating fluke lesion; (C) dorsal hematoma; (D) parasite cyst; (E) multiple lacerations in the ventral area and everted penis; (F) abscess near the bladder; and (G) detail of the head showing the epibionts in erupted teeth.

where the teeth crossed over, which was a sign of its adult age. Blubber thickness was thinner in the cranial area (7 cm) and thicker in the dorsal fin insertion area (7.5 cm). Multiple cysts (0.5 cm in diameter) of the cestode *Phyllobothrium* spp. were found in the adipose tissue near the caudal peduncle (Figure 4D).

Internal examination revealed abundant sero-sanguineous fluid in the thoracic cavity, congested lungs, and abundant liquid contained in the right pleura. These fluids were most likely caused by the defrosting process (Roe et al., 2012). The abdominal cavity presented two findings: (1) the main stomach had cephalopod beaks and fish otoliths and (2) a 2 cm abscess was located near the bladder (Figure 4F). Critical organs were weighed (Table 2), and additional analyses were performed, such as a cytology of the blowhole, blood, and spleen, which all presented normal

bacteria associated with postmortem findings. The low definition of the x-rays performed may have been due to the size of the carcass or to a low accuracy of the kilovoltage used.

The cause of death of the studied specimen could not be determined given the general background of the event, the degree of tissue degradation, and the macroscopic findings. Processes such as autolysis and freezing/thawing impede an appropriate histological evaluation as they alter morphometry and usually mask the cause of death (Rowles et al., 2001; Roe et al., 2012). Strandings can occur due to a variety of causes. Natural causes include predation, diseases, parasites, injury, and biotoxins, while anthropogenic causes include entanglement, exposure to noise pollution (e.g., seismic tests, sonar, and shipping; MacLeod & D'Amico, 2006; Bernaldo de Quirós et al., 2019), vessel strikes, and harassment by tourists (Moore et al., 2018).

The necropsy revealed (unrelated to the stranding itself and the following decomposition) parasitism by *Phyllobothrium* spp. in the adipose tissue of the peduncle, an abscess, and a dorsal hematoma. The presence of *Phyllobothrium* spp. has been related elsewhere to deep pelagic foraging species that prey on squid (Loizaga de Castro et al., 2014; Santoro et al., 2018). This parasite rarely causes severe infections in small cetaceans (Sweeney & Ridgway, 1975). It has been suggested that marine mammals may be intermediate hosts (Aznar et al., 2007; Santoro et al., 2018). In the United States, a stranded pygmy sperm whale

Table 2. Observed weights of various organs at necropsy of the stranded STW near Caleta Tortel in March 2019

Organs	Weight (kg)
Lungs with trachea	22.1
Heart	5.6
Stomach without content	5.7
Intestines	7.6
Liver	6.0

(*Kogia breviceps*; cause of death unknown, but main lesions were renal) in Florida was infested with this cestode, but lesions were not associated with that parasitic infection either (Rousselet et al., 2019). Therefore, the infestation on the STW was not likely the cause of its death.

Cetacean strandings have provided critical insights into distribution, population structure, and phylogeny (Bilgmann et al., 2011). Live strandings are unusual and a great opportunity to obtain information on cryptic species, emphasizing the need for a more robust and methodical whale stranding network in Chile. Additionally, collaborative work, when facing a stranding of an understudied species in an isolated site, proved essential for collecting the most accurate and complete data possible for review.

Acknowledgments

We would like to thank SERNAPESCA, SERNAPESCA Aysén, Museo Nacional de Historia Natural, Municipalidad de Tortel, Capitanía de Puerto Tortel, Alex Leiva from ALCAFAL company, and Rodrigo Mansilla of COPAS Sur Austral Center for their support in transferring the animal from the stranding site to the refrigerated truck. We would also like to thank the Escuela de Medicina Veterinaria, Campus Colina, Facultad de Ciencias de la Vida of the Universidad Andrés Bello for providing the room, staff, and equipment necessary for the necropsy. W. Espejo is supported by the Vicerrectoría de Investigación y Desarrollo of the Universidad de Concepción through postdoc 219.153.026-P. We would like to extend our special thanks to Oscar Legue, who carefully transported the ziphiid throughout its journey, and Ricardo Concha for his great disposition.

Literature Cited

- Aljanabi, S., & Martínez, I. (1997). Universal and rapid salt-extraction of high-quality genomic DNA for PCR-based techniques. *Nucleic Acids Research*, 25(22), 4692-4693. <https://doi.org/10.1093/nar/25.22.4692>
- Asociación de Médicos Veterinarios de Fauna Silvestre (AMEVEFAS). (2017). *Manual de necropsia de odontocetos* [Odontocete necropsy manual]. www.amevefas.cl/wp-content/uploads/2017/06/Manual-de-Necropsia-de-Odontocetos-AMEVEFAS-20171.pdf
- Aznar, F. J., Agustí, C., Littlewood, D. T. J., Raga, J. A., & Olson, P. D. (2007). Insight into the role of cetaceans in the life cycle of the tetraphyllideans (Platyhelminthes: Cestoda). *International Journal for Parasitology*, 37(2), 243-255. <https://doi.org/10.1016/j.ijpara.2006.10.0100>
- Bandelt, H. J., Forster, P., & Röhl, A. (1999). Median-joining networks for inferring intraspecific phylogenies. *Molecular Biology and Evolution*, 16(1), 37-48. <https://doi.org/10.1093/oxfordjournals.molbev.a026036>
- Barnett, J., Bernaldo de Quirós, Y., Dagleish, M. P., Davison, N., Deaville, R., ten Doeschate, M., Fernández-Rodríguez, A. J., Grilo, M., Gröne, A., Jauniaux, T., Jepson, P. D., van Neer, A., Perkins, M. W., Reckendorf, A., & Siebert, U. (2018, September). In L. L. IJsseldijk & A. W. Brownlow (Eds.), *Cetacean pathology: Necropsy technique & tissue sampling*. 24th ASCOBANS Advisory Committee Meeting, Funchal, Portugal.
- Bernaldo de Quirós, Y., Fernández, A., Baird, R. W., Brownell, R. L., Aguilar de Soto, N., Allen, D., Arbelo, M., Arregui, M., Costidis, A., Fahlman, A., Frantzis, A., Gulland, F. M. D., Iniguez, M., Johnson, M., Komnenou, A., Koopman, H., Pabst, D. A., Roe, W. D., Sierra, E., Tejedor, M., & Schorr, G. (2019). Advances in research on the impacts of anti-submarine sonar on beaked whales. *Proceedings of the Royal Society B: Biological Sciences*, 286(1895), 20182533. <https://doi.org/10.1098/rspb.2018.2533>
- Bilgmann, K., Möller, L. M., Harcourt, R. G., Kemper, C. M., & Beheregaray, L. B. (2011). The use of carcasses for the analysis of cetacean population genetic structure: A comparative study in two dolphin species. *PLOS ONE*, 6(5), e20103. <https://doi.org/10.1371/journal.pone.0020103>
- Dalebout, M. L., van Helden, A., Van Waerebeek, K., & Baker, C. S. (1998). Molecular genetic identification of Southern Hemisphere beaked whales (Cetacea: Ziphiidae). *Molecular Ecology*, 7, 687-694. <https://doi.org/10.1046/j.1365-294x.1998.00380.x>
- Dalebout, M., Baker, C., Mead, J., Cockcroft, V., & Yamada, T. (2004). A comprehensive and validated molecular taxonomy of beaked whales, Family Ziphiidae. *Journal of Heredity*, 95(6), 459-473. <https://doi.org/10.1093/jhered/esh054>
- Dalebout, M., Mead, J., Baker, C., Baker, A., & van Helden, A. (2002). A new species of beaked whale *Mesoplodon perrini* sp. N. (Cetacea: Ziphiidae) discovered through phylogenetic analyses of mitochondrial DNA sequences. *Wiley Online Library*, 18, 577-608. <https://doi.org/10.1111/j.1748-7692.2002.tb01061.x>
- Dalebout, M. L., Robertson, K. M., Frantzis, A., Engelhaupt, D., Mignucci-Giannoni, A. A., Rosario-Delestre, R. J., & Baker, C. S. (2005). Worldwide structure of mtDNA diversity among Cuvier's beaked whales (*Ziphius cavirostris*) implications for threatened populations. *Molecular Ecology*, 14(11), 3353-3371. <https://doi.org/10.1111/j.1365-294X.2005.02676.x>
- Gibbons, J., Gazitúa, F., & Venegas, C. (2000). Cetáceos en el estrecho de Magallanes y senos Otway, Skyring y Almirantazgo [Cetaceans in the Strait of Magellan and Otway, Skyring and Admiralty coves]. *Anales Instituto Patagonia*, 28, 107-118.
- International Whaling Commission (IWC). (2007). *Progress report on cetacean research, April 2006 to April 2007, with statistical data for the season 2006/07. Chile*. <https://iwc.int/private/downloads/6rTBVJ0i-bGAhEJ9Fhtjog/SC-59-ProgRepChile.pdf>

- Kearse, M., Moir, R., Wilson, A., Stones-Havas, S., Cheung, M., Sturrock, S., Buxton, S., Cooper, A., Markowitz, S., Duran, C., Thierer, T., Ashton, B., Meintjes, P., & Drummond, A. (2012). *Geneious Basic*: An integrated and extendable desktop software platform for the organization and analysis of sequence data. *Bioinformatics*, 28(12), 1647-1649. <https://doi.org/10.1093/bioinformatics/bts199>
- Kim, S. M., Eo, K. Y., Oh, J. W., Lee, Y. R., & Yoo, M. H. (2019). First record of ginkgo-toothed beaked whale (*Mesoplodon ginkgodens*) stranded in Korea. *The Journal of Veterinary Medical Science*, 81(8), 1223-1228. <https://doi.org/10.1292/jvms.19-0001>
- Loizaga de Castro, R., Vales, D., Degradi, M., García, N., Fernández, M., & Crespo, E. (2014). First record of cestode cysts of *Phyllobothrium delphini* (Phyllobothriidae) from dusky dolphins (*Lagenorhynchus obscurus*) off Argentine coast. *Hidrobiológica*, 24(3), 307-310.
- MacLeod, C. (1998). Intraspecific scarring in odontocete cetaceans: An indicator of male "quality" in aggressive social interactions? *Journal of Zoology*, 244(1), 71-77. <https://doi.org/10.1111/j.1469-7998.1998.tb00008.x>
- MacLeod, C. (2018). Beaked whales, overview. In B. Würsig, J. G. M. Thewissen, & K. M. Kovacs (Eds.), *Encyclopedia of marine mammals* (3rd ed., pp. 80-83). Academic Press. <https://doi.org/10.1016/B978-0-12-804327-1.00062-5>
- MacLeod, C., & D'Amico, A. (2006). A review of beaked whale behaviour and ecology in relation to assessing and mitigating impacts of anthropogenic noise. *Journal of Cetacean Research and Management*, 7(3), 211-221.
- MacLeod, C. D., & Herman, J. S. (2007). Development of tusks and associated structures in *Mesoplodon bidens* (Cetacea, Mammalia). *Mammalia*, 68(2-3), 175-184. <https://doi.org/10.1515/mamm.2004.018>
- Moore, K. M., Simeone, C. A., & Brownell, R. L. (2018). Strandings. In B. Würsig, J. G. M. Thewissen, & K. M. Kovacs (Eds.), *Encyclopedia of marine mammals* (3rd ed., pp. 945-951). Academic Press. <https://doi.org/10.1016/B978-0-12-804327-1.00249-1>
- Otley, H., Smith, J., & Dalebout, M. L. (2012). Beaked whale strandings on the Falkland Islands and South Georgia, South Atlantic Ocean, between 1866 and 2008. *Journal of the Marine Biological Association of the United Kingdom*, 92(8), 1851-1864. <https://doi.org/10.1017/S0025315411000749>
- Pitman, R. (2018). *Mesoplodon* beaked whales. In B. Würsig, J. G. M. Thewissen, & K. M. Kovacs (Eds.), *Encyclopedia of marine mammals* (3rd ed., pp. 595-602). Academic Press. <https://doi.org/10.1016/B978-0-12-804327-1.00172-2>
- Roe, W. D., Gartrell, B. D., & Hunter, S. A. (2012). Freezing and thawing of pinniped carcasses results in artefacts that resemble traumatic lesions. *Veterinary Journal*, 194(3), 326-331. <https://doi.org/10.1016/j.tvjl.2012.03.028>
- Rosario-Delestre, R., Rodríguez-López, M., Mignucci-Giannoni, A., & Mead, J. (1999). New records of beaked whales (*Mesoplodon* spp.) for the Caribbean. *Caribbean Journal of Science*, 35(1-2), 144-148.
- Rousselet, E., Stolen, M., Durden, W. N., Jablonski, T., Stacy, N. I., & Rotstein, D. S. (2019). Bilateral polycystic kidneys and focal renal cystadenoma in a pygmy sperm whale (*Kogia breviceps*). *Journal of Wildlife Diseases*, 55(1), 258-261. <https://doi.org/10.7589/2018-01-019>
- Rowles, T. K., Van Dolah, F. M., & Hohn, A. A. (2001). Gross necropsy and specimen collection protocols. In L. A. Dierauf & F. M. D. Gulland (Eds.), *CRC handbook of marine mammal medicine* (2nd ed). CRC Press. <https://doi.org/10.1201/9781420041637.ch21>
- Sambrook, J., Fritsch, E. F., & Maniatis, T. (1989). *Molecular cloning: A laboratory manual* (2nd ed.). Cold Spring Harbor Laboratory.
- Santoro, M., Di Nocera, F., Iaccarino, D., Cipriani, P., Guadano Procesi, I., Maffucci, F., Hochscheid, S., Blanco, C., Cerrone, A., Galiero, G., Nascetti, G., & Mattiucci, S. (2018). Helminth parasites of the dwarf sperm whale *Kogia sima* (Cetacea: Kogiidae) from the Mediterranean Sea, with implications on host ecology. *Diseases of Aquatic Organisms*, 129(3), 175-182. <https://doi.org/10.3354/dao03251>
- Sielfeld, W. (1979). Consideraciones acerca de tres especies de *Mesoplodon gervais* (Cetacea: Ziphiidae) presentes en aguas Chilenas [Considerations about three species of *Mesoplodon gervais* (Cetacea: Ziphiidae) present in Chilean waters]. *Anales Instituto Patagonia*, 10, 179-187.
- Sweeney, J. C., & Ridgway, S. H. (1975). Common diseases of small cetaceans. *Journal of the American Veterinary Medical Association*, 167(7), 533-540.
- Taylor, B. L., Baird, R., Barlow, J., Dawson, S. M., Ford, J., Mead, J. G., Notarbartolo di Sciara, G., Wade, P., & Pitman, R. L. (2008). *Mesoplodon layardii*. In International Union for Conservation of Nature (Ed.), *The IUCN red list of threatened species 2008: e.T13249A3429897*. <https://doi.org/10.2305/IUCN.UK.2008.RLTS.T13249A3429897.e>
- Venegas, C., & Sielfeld, W. (1978). Registros de *Mesoplodon layardii* y otros cetáceos en Magallanes [Records of *Mesoplodon layardii* and other cetaceans in Magallanes]. *Anales Instituto Patagonia*, 9, 171-178.