

# A North Carolina Stranding of a White-Beaked Dolphin (*Lagenorhynchus albirostris*), Family Delphinidae: A New Southerly Record

Victoria G. Thayer,<sup>1,2</sup> Craig A. Harms,<sup>3</sup> Keith A. Rittmaster,<sup>4</sup>  
David S. Rotstein,<sup>5</sup> and John E. Hairr<sup>4</sup>

<sup>1</sup>North Carolina Division of Marine Fisheries, 3441 Arendell Street, Morehead City, NC 28557, USA  
E-mail: vgthayer@gmail.com

<sup>2</sup>North Carolina State University, Center for Marine Sciences and Technology,  
303 College Circle, Morehead City, NC 28557, USA

<sup>3</sup>Department of Clinical Sciences, College of Veterinary Medicine and Center for Marine Sciences and Technology,  
North Carolina State University, 303 College Circle, Morehead City, NC 28557, USA

<sup>4</sup>North Carolina Maritime Museum, 315 Front Street, Beaufort, NC 28516, USA

<sup>5</sup>Marine Mammal Pathology Services, Olney, MD 20832, USA

## Abstract

An adult 273.7-kg, 266-cm male white-beaked dolphin (*Lagenorhynchus albirostris*) stranded in Beaufort, North Carolina, on 16 April 2015 at 34.698125 N, -76.650476 W. Morphometrics, gross necropsy, and histopathologic evaluation were performed. Bilateral adrenal gland tumors (pheochromocytomas) were found and may have contributed to stranding. This is the first recorded white-beaked dolphin specimen to strand along the North Carolina coast, and it is the most southerly reported stranding of a white-beaked dolphin in the world.

**Key Words:** pheochromocytoma, white-beaked dolphin, *Lagenorhynchus albirostris*, stranding, Beaufort, North Carolina

## Introduction

### Background

The white-beaked dolphin (*Lagenorhynchus albirostris*) was described by Gray (1846) based on a dolphin caught off Great Yarmouth, England, and first reported by Brightwell (1846) as *Delphinus tursio*, Fabricius, 1780. Gray described the dolphin as a new genus and species, and the skeleton of this specimen currently resides in the British Museum of Natural History.

White-beaked dolphins are broadly distributed in cold North Atlantic waters between latitudes of 40° to -80° (Jefferson et al., 2015; Figure 1). The white-beaked dolphin is the more northerly species of *Lagenorhynchus* found in the Atlantic Ocean; it is endemic to the subpolar and cold temperate North Atlantic continental shelf and offshore

waters; and it is also seen in coastal waters (Kinze, 2002). The species is abundant and is listed as one of Least Concern by the International Union for Conservation of Nature (IUCN) as there have been neither reported population declines nor identified threats (Hammond et al., 2012). A population minimum of several thousand is currently estimated to exist in the northwestern Atlantic, and populations in the northeastern Atlantic may be greater than 100,000 (Hammond et al., 2012).

Morphological differences have been found between white-beaked dolphins of the eastern and western Atlantic (Mikkelsen & Lund, 1994). The genus *Lagenorhynchus* is believed to be a polyphyletic taxon (Cipriano, 1997; LeDuc et al., 1999; McGowen, 2011). LeDuc et al. (1999) predict that future genetic work will split out other *Lagenorhynchus* in this genus, and *L. albirostris* will be the only remaining member, although recent taxonomic reviews have not separated the *Lagenorhynchus* (Committee on Taxonomy, 2016).

White-beaked dolphins are robust animals that reach a maximum length of approximately 3.1 m, weigh up to 350 kg, and have short, thick rostra (Leatherwood et al., 1976; Kinze, 2002). The dorsal fins are large, rounded at the peak, and slightly falcate. Color patterns vary, but the animals are mostly dark gray to black and have white mottled or spotted beaks and ventral areas. The rostra are separated from the melon by a slight crease, and thoracic white patches connect to whitish gray saddles and light streaks above and below the eyes (Reeves et al., 1999; Jefferson et al., 2015). From a distance, white-beaked dolphins may be confused with the smaller, more slender Atlantic white-sided dolphins (*Lagenorhynchus*

*acutus*) (Jefferson et al., 2015). The stockier white-beaked dolphins have a white tail stock and do not have the white-sided dolphin's yellow patch on the lateral tail stock. Vernacular names include squid hound, springer, scoulter, and herring hogs (Reeves et al., 1999). Fishermen along the coast of Labrador who actively hunted these dolphins into the 1980s referred to them as “jumpers” (Alling & Whitehead, 1987).

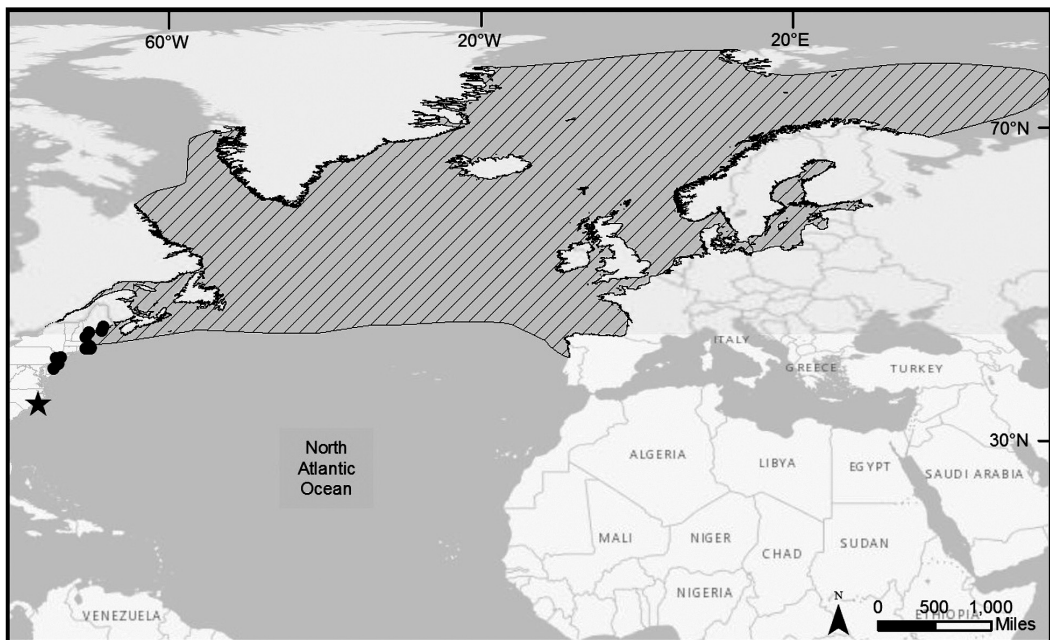
In U.S. waters, white-beaked dolphin sightings have been concentrated in the Gulf of Maine and around Cape Cod (Jefferson et al., 2015). On the U.S. East Coast, stranding records prior to the case presented herein have ranged from Maine to New Jersey (National Oceanic and Atmospheric Administration [NOAA] Marine Mammal Health and Stranding Response National Database).

As of this writing, there were 18 records of white-beaked dolphin strandings in the NOAA Fisheries Service, Greater Atlantic Regional Fisheries Office's Marine Mammal Health and Stranding Response National Database from 1800 to 2016 (consulted 29 September 2017). All of these occurred in the Greater Atlantic Region between 1989 and 2014 in Maine, Massachusetts, New York, and New Jersey (Figure 1). The Smithsonian Institution's collection includes 16 *L. albirostris* specimens: the earliest is from Norway in 1890, and the remaining 15 from 1903 to 1983. The most southern *L. albirostris* specimen in the collection is from Massachusetts.

Mention of *L. albirostris* is absent from earlier published surveys of marine mammals from the waters off the southeastern U.S. (Caldwell & Golley, 1965; Schmidley, 1981).

There are 21 Ocean Biogeographic Information System (OBIS) datasets that include 1,986 live sighting records of white-beaked dolphins in the western North Atlantic from 1913 to 2015 (Halpin et al., 2009). An aerial survey conducted between 1978 and 1982 as part of the University of Rhode Island's Bureau of Land Management-sponsored Cetacean and Turtle Assessment Program (CETAP) identified 573 of these animals along the continental shelf between Cape Hatteras and Nova Scotia. The southernmost sighting to date was a group of 15 white-beaked dolphins spotted by CETAP observers in May of 1979 approximately 105 km offshore of Currituck County, near the North Carolina and Virginia border, at 36.23333 N, -74.78333 W, close to the edge of the continental shelf (Winn, 1982). Prior to the 1979 sighting off North Carolina, the most southerly confirmed sighting of white-beaked dolphins was in the eastern North Atlantic, approximately 265 km off Cape St. Vincent, Portugal, where five of these animals were spotted by Dutch researchers on 15 May 1947 at 37.00000 N, 12.50000 W (Bierman & Slijper, 1948).

There have been other reports of sightings of white-beaked dolphins in the vicinity of the Strait of Gibraltar as well as unconfirmed reports



**Figure 1.** Range of white-beaked dolphin (*Lagenorhynchus albirostris*) (in horizontal shading), stranding locations (dots), and North Carolina stranding location (star)

from the coast of Turkey (Reeves & Notarbartolo di Sciara, 2006). However, none of these reports were as far south as the group spotted in 1979 off North Carolina ( $36^{\circ}$  N). The current report documents a new southernmost record of white-beaked dolphins on either side of the Atlantic.

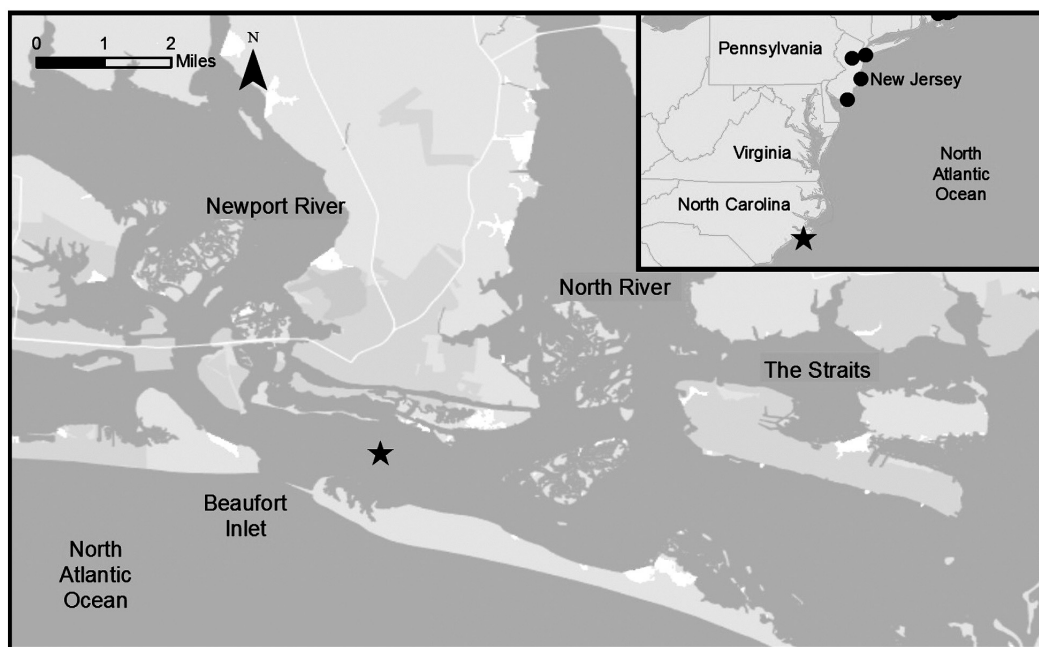
### Stranding

At noon on 16 April 2015, a tour boat operator reported to the Marine Mammal Stranding Network that an unidentified marine mammal was thrashing on the beach of Sand Dollar Island, a dredge spoil island located at  $34.698125^{\circ}$  N,  $-76.650476^{\circ}$  W, in Back Sound between Shackleford Banks and Carrot Island near Beaufort in Carteret County, North Carolina (Figure 2). First responder examination and photographs facilitated the positive identification of a white-beaked dolphin.

Responders from the nearby North Carolina Maritime Museum were first on the scene at approximately 1300 h and found the animal alive but in serious condition (Figure 3). Other stranding team members, including the lead author and two veterinarians, arrived at 1400 h. The tide had been low at 1225 h and was rising on a very low shoal. The air temperature at 1300 h was  $20.3^{\circ}\text{C}$ , water temperature was  $16.9^{\circ}\text{C}$ , and winds were 10 to 15 kts from the east-southeast (<http://tidesandcurrents.noaa.gov>). The dolphin was upright in a shallow trench, leaning slightly to the left. The

animal externally appeared to be in good body condition and exhibited steady fluke slapping. It was responsive to touch, but its eyes did not follow movement. The skin was cracked over approximately 50% of the body surface; there were bleeding ulcerations on the left fluke; and the cornea of the right eye was ulcerated. The initial respiratory rate ranged from two to seven per minute. The heart rate was 60 beats per minute and irregular, but not a typical sinus arrhythmia associated with respiratory pattern.

Because the animal was well out of its normal habitat, south and inshore, and was a single animal stranding with extensive skin deterioration and with no rehabilitation facility options, euthanasia was recommended and approved by the National Marine Fisheries Service, Southeast Regional Stranding Office, in St. Petersburg, Florida. Midazolam ( $0.08\text{ mg/kg}$ ), acepromazine ( $0.8\text{ mg/kg}$ ), and xylazine ( $1.6\text{ mg/kg}$ ) were given intramuscularly starting at 1403 h. These doses were based on a 225-kg estimated weight and were back-calculated from the actual weight of 273.7 kg. There was some activity during the sedation and some moderate fluking throughout. Arching commenced at 1420 h, followed by some swimming movements, violent arching, fluke slapping, and snorts. The fluking was pronounced, but not unusual for a *Lagenorhynchus* sp. The time of death was 1423 h. No euthanasia solution



**Figure 2.** Map of stranding location of white-beaked dolphin on 16 April 2015; inset map shows closest previous strandings of white-beaked dolphins.



was needed, indicating the degree of debilitation of the dolphin. Blood was collected immediately postmortem on site from cardiac puncture using a 17-gauge, 20-cm needle. Blood analysis at North Carolina State Center for Marine Sciences and Technology (NC State CMAST) indicated that the dolphin was dehydrated (PCV 54%, TS 9.0 g/dL, TP 8.2 g/dL) and hyperglycemic (Glu 191 mg/L). The PCV and TS were from spun

hematocrit capillary tubes and refractometry of the resulting plasma. The TP and glucose were from VetScan VS2 (Abaxis, Union City, CA, USA).

The carcass was loaded onto the vessel *Spyhop* and taken to the chiller (3° C) at NC State University CMAST in Morehead City for over-night storage. A detailed necropsy commenced 15 h after death.



**Figure 3.** Stranded white-beaked dolphin in Beaufort, North Carolina, on 16 April 2015 (Photo credit: K. Rittmaster)

### Postmortem Examination

Postmortem findings in this mature, 273.7-kg, 266-cm male included a variety of health issues, including some that would likely have influenced behavior and physiology.

Notable gross and histologic pathology identified included a tumor of the left testis (seminoma), right shoulder osteoarthritis restricting range of motion of the pectoral fin, gas emboli in superficial testicular vessels, gas accumulation around the shoulders, pulmonary edema, hepatic fibrosis and cyst formation, renal interstitial fibrosis, mild to moderate myocardial fibrosis, thyroid gland nodular hyperplasia, thymic macrocysts, salivary gland impaction, tonsillitis, and bilateral adrenal gland tumors (pheochromocytomas). Lung, lung lymph node, and cervical spinal cord tissue samples were polymerase chain reaction (PCR) tested for cetacean morbillivirus by the University of Georgia–Athens Veterinary Diagnostic Laboratory and were negative. Cervical spinal cord and brain stem tissues were PCR-tested for *Brucella* sp. by the University of Illinois’s Zoological Pathology Program Molecular Diagnostic Laboratory and were negative.

Skeletal preparation revealed that thoracic vertebrae nine and ten were fused with complete loss of the intervertebral disc spacing. The transverse and spinous processes exhibited roughening of the surface with boney loss and sites of boney proliferation, and there was flattening of the articular processes. The vertebral body had patchy bone loss and thinning. The right scapulohumeral articular joint surface was pitted and roughened, and the joint surface was shallow. The head of the humerus

was irregular with boney loss and proliferation, and the neck of the humerus was broadened.

Of these many abnormalities, several are either incidental findings (e.g., seminoma and thymic macrocysts) or results of the stranding process (e.g., gas emboli and gas accumulation around the shoulders from inability to dive and regulate dissolved gas tension after stranding and possibly prior to stranding; Dennison et al., 2011) and pulmonary edema from cardiovascular collapse. Bilateral pheochromocytomas, however, are clinically noteworthy pathological findings.

Based on necropsy and histopathology findings of bilateral pheochromocytomas, plasma archived at -70°C was submitted for normetanephrine and metanephrine measurement (normetanephrine, 2.9 nmol/L; metanephrine, 18.0 nmol/L; Associated Regional and University Pathologies, Animal Reference Pathology, Salt Lake City, UT, USA). Pheochromocytomas overproduce catecholamines, including norepinephrine and epinephrine. Clinical signs in humans, dogs, and cats can include headache, hypertension, weakness and collapse, exercise intolerance, gastrointestinal distress, cardiac arrhythmias, anxiety and pacing (McNiel & Husbands, 2005), agitation, tachypnea and hyphema in cats (Wimpole et al., 2010), lethargy, and tachyarrhythmia and collapse in dogs (Gostelow et al., 2013). In this dolphin, pheochromocytomas may have contributed to its out-of-range location. Seminomas and pheochromocytomas have previously been reported in cetaceans but without plasma measures supporting functional status of the pheochromocytomas (Estep et al., 2005).

**Table 1.** Plasma normetanephrine and metanephrine values in several species

|   | Normetanephrine (nmol/L) | Metanephrine (nmol/L) |
|---|--------------------------|-----------------------|
| Humans <sup>1</sup>   | 0.0-0.89                 | 0.0-0.49              |
| Dogs <sup>2</sup> ( <i>Canis lupus familiaris</i> )   | 1.00-3.03                | 0.94-2.57             |
| Cats <sup>3</sup> ( <i>Felis catus</i> )  | 2.47-4.55                | 0.41-1.80             |
| Harbor porpoise <sup>4</sup> ( <i>Phocoena phocoena</i> )<br>Free-ranging post-capture                    | 2.67-9.42                | 0.80-11.52            |
| Harbor porpoise <sup>4</sup> ( <i>P. phocoena</i> )<br>Rehabilitation                                     | 0.70-5.89                | 0.38-4.34             |
| Harbor porpoise <sup>4</sup> ( <i>P. phocoena</i> )<br>Long-term human care                               | 2.02-2.30                | 0.42-0.50             |
| Bottlenose dolphin <sup>5</sup> ( <i>Tursiops truncatus</i> )<br>Health assessment captures, Sarasota, FL | 0.92-1.58                | 2.83-5.57             |
| White-beaked dolphin <sup>6</sup> ( <i>Lagenorhynchus albirostris</i> )                                   | 2.9                      | 18.0                  |

<sup>1</sup>ARUP Laboratories, Salt Lake City, UT, <http://ltd.aruplab.com/Tests/Pub/0050184>; <sup>2</sup>Green & Frank, 2013; <sup>3</sup>Wimpole et al., 2010; <sup>4</sup>Müller et al., 2013; <sup>5</sup>C. Harms, unpub. data, & R. Wells, Sarasota Dolphin Research Program, Chicago Zoological Society; <sup>6</sup>KAR 40, stranded white-beaked dolphin in this manuscript

Metanephrines—normetanephrene and metanephrene—are the O-methylated metabolites of norepinephrine and epinephrine, respectively (Lenders & Eisenhofer, 2004). They are used to diagnose pheochromocytomas because their concentrations in circulation are less affected by short-term stressors than are their parent compounds. Although normal plasma concentrations of metanephrines in white-beaked dolphins are unknown, concentrations from this dolphin (normetanephrene, 2.9 nmol/L; metanephrene, 18.0 nmol/L) may be compared with reported values and reference intervals from other species, including humans (Table 1). Plasma concentration of normetanephrene from this white-beaked dolphin exceeded the ranges for humans and bottlenose dolphins, and the concentration of metanephrene exceeded the range for all the above species. The effect of stranding on plasma concentrations of metanephrines in cetaceans, irrespective of the presence of pheochromocytomas, still needs to be investigated.

Marine mammal stranding personnel are frequently unable to determine a cause of death for stranded animals, even in the case of very fresh specimens, complete pathological evaluation, and ancillary diagnostics. Out-of-range stranded animals offer additional challenges in these cases. In the current case, a complete necropsy with archiving of frozen and preserved biological samples allowed a logical and methodical determination of the probable cause of stranding. Although pheochromocytomas are an uncommon finding, dysfunction of any organ system may lead to abnormal behavior or disrupt homeostasis, culminating in stranding. Future testing of metanephrene and normetanephrene concentrations in both healthy and live stranded animals could contribute useful baseline data to distinguish effects of acute and chronic stimulation of the adrenal medulla that might be associated with stranding and longer term conditions leading to stranding from pathological effects of pheochromocytoma.

This specimen extends the range of *L. albirostris* 240 km southwest of where the species was previously observed offshore from the North Carolina/Virginia border, and 500 km south of where the most southerly previously recorded stranding occurred at Cape May, New Jersey, in May of 2007. The animal found on Sand Dollar Island in Back Sound near Beaufort has the distinction of being the most southerly stranding record for a white-beaked dolphin anywhere in the world. The skeleton of this specimen is currently being prepared by the North Carolina Maritime Museum in Beaufort for rearticulation and display.

## Acknowledgments

We are grateful for the assistance of the North Carolina Marine Mammal Stranding Partners, particularly W. McLellan and D. A. Pabst. B. Gupton (North Carolina Division of Marine Fisheries Marine Patrol), J. Krause (North Carolina State University), M. Lewis (Harkers Island Fire Department), B. Mauney (North Carolina Maritime Museum), B. Myers (Harkers Island Fire Department), L. Pallin (Duke University Marine Laboratory), J. Sullivan (North Carolina Division of Marine Fisheries and North Carolina State Center for Marine Sciences and Technology), and J. Summers (North Carolina Maritime Museum) assisted with the stranding response. We are indebted to R. Wells and the Sarasota Dolphin Research Program for facilitating the collection of samples from free-ranging bottlenose dolphins (National Marine Fisheries Service Scientific Research Permit No. 15543). We thank M. Voss (North Carolina Division of Marine Fisheries) for creating the maps. We are grateful to the NOAA Fisheries Service, Greater Atlantic Regional Fisheries Office and the Greater Atlantic Region Marine Mammal Stranding Network for the stranding data from the Marine Mammal Health and Stranding Response National Database. This work was funded by the John H. Prescott Grant NA14NMF4390181.

## Literature Cited

- Alling, A. K., & Whitehead, H. P. (1987). A preliminary study of the status of white-beaked dolphins, *Lagenorhynchus albirostris*, and other small cetaceans off the coast of Labrador. *Canadian Field-Naturalist*, 101(2), 131-135.
- Bierman, W. H., & Slijper, E. J. (1948). Remarks upon the species of the genus *Lagenorhynchus* II. *Proceedings Koninklijke Nederlandsche Akademie van Wetenschappen*, 51, 127-133.
- Brightwell, T. (1846). Observations on a specimen of the bottle-nosed dolphin, *Delphinus tursio*, Fabr., taken at Great Yarmouth, October 1845. *Annals and Magazine of Natural History*, 17(109), 21-22. <https://doi.org/10.1080/037454809496434>
- Caldwell, D. K., & Golley, F. B. (1965). Marine mammals from the coast of Georgia to Cape Hatteras. *Journal of the Elisha Mitchell Scientific Society*, 81, 24-32.
- Cipriano, F. (1997). Antitropical distributions and speciation in dolphins of the genus *Lagenorhynchus*: A preliminary analysis. In A. E. Dizon, S. J. Chivers, & W. F. Perrin (Eds.), *Molecular genetics of marine mammals* (The Society for Marine Mammalogy, Special Publication 3, pp. 305-316). Lawrence, KS: Allen Press, Inc.
- Committee on Taxonomy. (2016). *List of marine mammal species and subspecies*. Lawrence, KS: The Society for Marine



- Mammalogy. Retrieved from [www.marinemammalscience.org](http://www.marinemammalscience.org)
- Dennison, S., Moore, M. J., Fahlman, A., Moore, K., Sharp, S., Harry, C. T., . . . Wells, R. S. (2011). Bubbles in live-stranded dolphins. *Proceedings of the Royal Society B: Biological Sciences*. <https://doi.org/10.1098/rspb.2011.1754>
- Estep, J. S., Baumgartner, R. E., Townsend, F., Pabst, D. A., McLellan, W. A., Friedlaender, A. S., . . . Lipscomb, T. P. (2005). Malignant seminoma with metastasis, sertoli cell tumor, and pheochromocytoma in a spotted dolphin (*Stenella frontalis*) and malignant seminoma with metastasis in a bottlenose dolphin (*Tursiops truncatus*). *Veterinary Pathology*, 42, 357-359. <https://doi.org/10.1354/vp.42-3-357>
- Gostelow, R., Bridger, N., & Syme, H. M. (2013). Plasma-free metanephrine and free normetanephrine measurement for the diagnosis of pheochromocytoma in dogs. *Journal of Veterinary Internal Medicine*, 3(27), 83-90. <https://doi.org/10.1111/jvim.12009>
- Gray, F. (1846). On the British Cetacea. *Annals and Magazine of Natural History*, 17(109), 82-85. <https://doi.org/10.1080/037454809495560>
- Green, B. A., & Frank, E. L. (2013). Comparison of plasma free metanephrines between healthy dogs and 3 dogs with pheochromocytoma. *Veterinary Clinical Pathology*, 42(4), 499-503. <https://doi.org/10.1111/vcp.12093>
- Halpin, P. N., Read, A. J., Fujioka, E., Best, B., Hazen, L., Kot, C., . . . Hyrenbach, K. D. (2009). OBIS-SEAMAP: The world data center for marine mammal, sea bird, and sea turtle distributions. *Oceanography*, 22(2), 104-115. <https://doi.org/10.5670/oceanog.2009.42>
- Hammond, P. S., Bearzi, G. A., Björge, A., Forney, K. A., Karczmarski, L., Kasuya, T., . . . Wilson, B. (2012). *Lagenorhynchus albirostris*. In International Union for Conservation of Nature (Ed.), *2012 IUCN red list of threatened species*. Gland, Switzerland: IUCN.
- Hershkovitz, P. (1966). *Catalog of living whales* (Bulletin 246). Washington, DC: Smithsonian Institution, U.S. National Museum. <https://doi.org/10.5479/si.03629236.246>
- Jefferson, T. A., Webber, M. A., & Pitman, R. L. (Eds.). (2015). *Marine mammals of the world: A comprehensive guide to their identification* (2nd ed.). London: Elsevier.
- Kinze, C. C. (2002). White-beaked dolphin *Lagenorhynchus albirostris*. In W. F. Perrin, B. Würsig, & J. G. M. Thewissen (Eds.), *Encyclopedia of marine mammals* (pp. 1332-1334). San Diego: Academic Press.
- Leatherwood, S., Caldwell, D. K., & Winn, H. E. (1976). *Whales, dolphins, and porpoises of the western North Atlantic: A guide to their identification* (NOAA Technical Report NMFS Circular 396). Washington, DC: National Oceanic and Atmospheric Administration.
- LeDuc, R., Perrin, W. F., & Dizon, A. E. (1999). Phylogenetic relationships among the delphinid cetaceans based on full cytochrome B sequences. *Marine Mammal Science*, 15(3), 619-648. <https://doi.org/10.1111/j.1748-7692.1999.tb00833.x>
- Lenders, J. W. M., & Eisenhofer, G. (2004). Normetanephrine and metanephrine. In L. Martini (Ed.), *Encyclopedia of endocrine diseases* (pp. 387-390). Cambridge, MA: Elsevier Publishing Co. <https://doi.org/10.1016/B0-12-475570-4/00929-X>
- McGowen, M. R. (2011). Toward the resolution of an explosive radiation: A multilocus phylogeny of oceanic dolphins (Delphinidae). *Molecular Phylogenetic Evolution*, 60(3), 345-357. <https://doi.org/10.1016/j.ympev.2011.05.003>
- McNiel, E., & Husbands, B. D. (2005). Pheochromocytoma. In S. J. Ettinger & E. C. Feldman (Eds.), *Textbook of veterinary internal medicine, Vol. II* (6th ed., pp. 1632-1638). St. Louis, MO: Elsevier Saunders.
- Mikkelsen, A. M. K., & Lund, A. (1994). Intraspecific variation in the dolphins *Lagenorhynchus albirostris* and *L. acutus* (Mammalia: Cetacea) in metrical and non-metrical skull characters, with remarks on occurrence. *Journal of Zoology*, 234(2), 289-299. <https://doi.org/10.1111/j.1469-7998.1994.tb06076.x>
- Müller, S., Lehnert, K., Seibel, H., Driver, J., Ronnenberg, K., Teilmann, J., . . . Siebert, U. (2013). Evaluation of immune and stress status in harbor porpoise (*Phocoena phocoena*): Can hormones and mRNA expression levels serve as indicators to assess stress? *BioMed Central Veterinary Research*, 9(145). Retrieved from [www.biomedcentral.com/1746-6148/9/145](http://www.biomedcentral.com/1746-6148/9/145)
- Reeves, R. R., & Notarbartolo di Sciara, G. (2006). *The status and distribution of cetaceans in the Black Sea and Mediterranean Sea* (Workshop report). Malaga, Spain: IUCN Centre for Mediterranean Cooperation. 137 pp.
- Reeves, R. R., Smeenk, C., Kinze, C. C., Brownell, R. L., Jr., & Lien, J. (1999). White-beaked dolphin (*Lagenorhynchus albirostris*) (Gray, 1846). In S. H. Ridgway & R. Harrison (Eds.), *Handbook of marine mammals, Vol. 6* (pp. 1-30). San Diego: Academic Press.
- Schmidley, D. J. (1981). *Marine mammals of the southeastern United States coast and the Gulf of Mexico* (FWS/OBS-80/41). Washington, DC: Office of Biological Services. 163 pp.
- Wimpole, J. A., Adagra, C. F. M., Billson, M. F., Pillai, D. N., & Foster, D. J. (2010). Plasma free metanephrines in healthy cats, cats with non-adrenal disease and a cat with suspected pheochromocytoma. *Journal of Feline Medicine and Surgery*, 12, 435-440. <https://doi.org/10.1016/j.jfms.2009.10.010>
- Winn, H. E. (1982). *A characterization of marine mammals and turtles in the Mid- and North Atlantic areas of the U.S. Outer Continental Shelf* (Final report of the Cetacean and Turtle Assessment Program, University of Rhode Island). Prepared for the U.S. Department of the Interior, Bureau of Land Management, Washington, DC, under Contract AA551-CT8-48. 538 pp.