

THE FATE OF OLD BOTTLE-NOSED DOLPHINS, *TURSIOPS TRUNCATUS*, IN NATURE AS REVEALED BY THE CONDITION OF THEIR SKELETONS.

W. M. A. de Smet

Univers. Antw. (RUCA), Veterinary Section, Antwerp (Belgium) and Koninklijk Belgisch Instituut voor Natuurwetenschappen, Vautierstraat, Brussels (Belgium).

Summary

Comparison of the skeletons of stranded or river-dwelling bottle-nosed dolphins with those of delphinarium specimens revealed that many of the former animals had suffered from various diseases.

Most wild specimens have broken or lost a part of their teeth or even all of them. In a few cases they show signs of bone erosion (probably by abscesses), bone neoformation, and in a single case a broken mandible. Teeth abrasion may start early in life. Also delphinarium specimens may have broken teeth.

Broken ribs can be found in half of the number of specimens. In the wild the ribs healed nicely, but in the delphinarium they hardly did. All the wild specimens show periosteitic phenomena to some degree. Delphinarium specimens are not excepted from them. In one of the old specimens foramina became partially occluded. Ankylosing hyperostosis is seen in two specimens.

It is advised that during autopsies attention is paid to the condition of the teeth, the solidity of the rib-cage and the general state of the skeleton.

Introduction

During the last few years the bottle-nosed dolphin, *Tursiops truncatus*, became one of the best studied cetacean species, because it is the most common one in delphinaria, zoos, dolphin shows and training experiments. Several museums are acquiring skulls and complete skeletons now from such delphinarium specimens. The older museum material was mostly collected from stranded specimens or from animals that had penetrated into the rivers.

In order to understand the condition of this older museum material, it should be borne in mind that when cetaceans get stranded, they generally are either too sick or too exhausted to resist the wave force or they have died some time before and their dead bodies are washed ashore. In particular in mass strandings other factors may be involved as well. River specimens are abnormal specimens too, being stragglers that have lost contact with the others, often because of a bad health. So, till recently, the museum material mostly consisted of full-grown, but abnormal specimens, whose complete appearance revealed that the last period of their life had been hard. Such skeletons are quite in contrast with those of delphinarium specimens, the latter being mostly young or not full-grown animals, living in other conditions than those struggling for life in nature (Fig. 1).

Comparisons between both categories are becoming possible now and a few interesting findings have been made, that may be of importance for a better understanding of ageing and pathology in these animals.

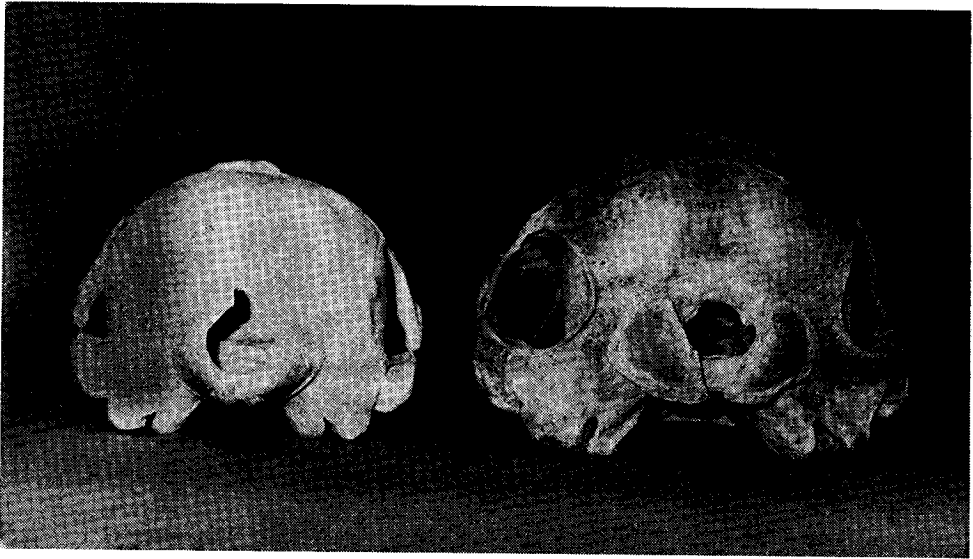

Figure 1
Posterior view of the skulls of two bottle-nosed dolphins. At left a female specimen, "Gibi" of the Antwerp Zoo, 2.39 m long, probably 8 years of age, imported from Florida. At right a very old female, 3.25 m long, caught in the river Scheldt in Belgium in 1934.

Study material

The collection of the Royal Belgian Institute of Natural Sciences in Brussels possesses twelve skeletons of the bottle-nosed dolphin (*Tursiops truncatus*).

- Four of them originate from the Antwerp Zoo delphinarium,
- five from strandings at the Belgian coast,
- two from specimens that had penetrated into the river Scheldt, and
- one from a specimen caught at sea between England and Ireland.

This material is not extensive enough to allow general conclusions. But the present findings may show already some orientation for research in coming periods.

General considerations

This research on the pathology is not new, a fair number of authors have already described deformations in cetacean skeletons. Among the recent ones attention must be drawn to a paper of VAN BREE and DUGUY (1970) on several pathological aberrations in the skeletons of cetaceans of the museums of Amsterdam and of La Rochelle, and on a paper of DE SMET (1972) on two specimens of the white-beaked dolphin, *Lagenorhynchus albirostris*, from the Belgian coast. Important as well are the different considerations made on the broken ribs of the fin-whale of the Oceanographical Museum in Monaco (BUCHANAN, 1910; SLIJPER, 1931; RODE, 1939). The most complete studies, however, are those of SLIJPER (1931 and 1936) which were in that time the best approaches to the interpretation of the pathological conditions.

Contrary to SLIJPER (1931) the author is of the opinion that it is too risky to conclude to what percentage these pathological conditions may exist, because stranded specimens or stragglers in rivers are not indicative for the population; they must be considered to be outsiders, who finally lost the struggle for life, because of increased lack of adaptation to the environment.

General findings

Although the material is still limited, the author gets the impression that :

- 1) tooth diseases are very common, even in delphinarium specimens,
- 2) broken ribs are more common than might be believed, even in delphinarium specimens, and they may be one of the factors causing pulmonary diseases,
- 3) rheumatic affections seem to be of quite a common occurrence in cetaceans.

The material of stranded specimens indicates that life may be hard for old dolphins in nature. One is tempted to conclude that bottle-nosed dolphins, and cetaceans in general, must be very strong animals, being able to survive with severe deformities of their skeletons.

Tooth diseases

Bottle-nosed dolphins have a high number of teeth, between 19 and 27 per row. This means that they may have between 76 and 108 teeth. All these teeth are similar in type, and all belong to a single generation : there is no tooth changing as in most other mammals.

In young dolphins the teeth are sharp and conical, and so they are in most delphinarium specimens. But the friction of the teeth of the lower jaw against those of the upper jaw when the mouth is closed, causes some wear. The position of the superior teeth in relation to the inferior teeth determines whether this wear may first appear on the anterior side of the teeth, or on the posterior side, or on the top. The wear may proceed quite quickly and may bring about incarved teeth, but also worn off teeth tops, even in specimens that have not yet reached full adult size.

As an example of this early tooth top wear may serve the mounted skeleton in the old exhibition room of the Brussels Institute. This specimen is the only one in this collection that was caught at sea. In many of its vertebrae the epiphyses are not yet connected to the diaphyses and this shows that the specimen still has to grow, although this skeleton reaches the unusual length of 3.32 m. The teeth of this dolphin are very worn down, even worse than in some completely full-grown specimens, and they have a truncate aspect (°).

(°) It is noteworthy that the first specimen of this species, that has been described in 1821 by MONTAGU, also had very truncate teeth. The author believed this to be a characteristic of the species, which he called therefore *Delphinus truncatus*. The illogical requirements of the zoological nomenclature have perpetuated this uncorrect epithet, even although the species has later been placed in the genus *Tursiops*, and is known now as *Tursiops truncatus*.

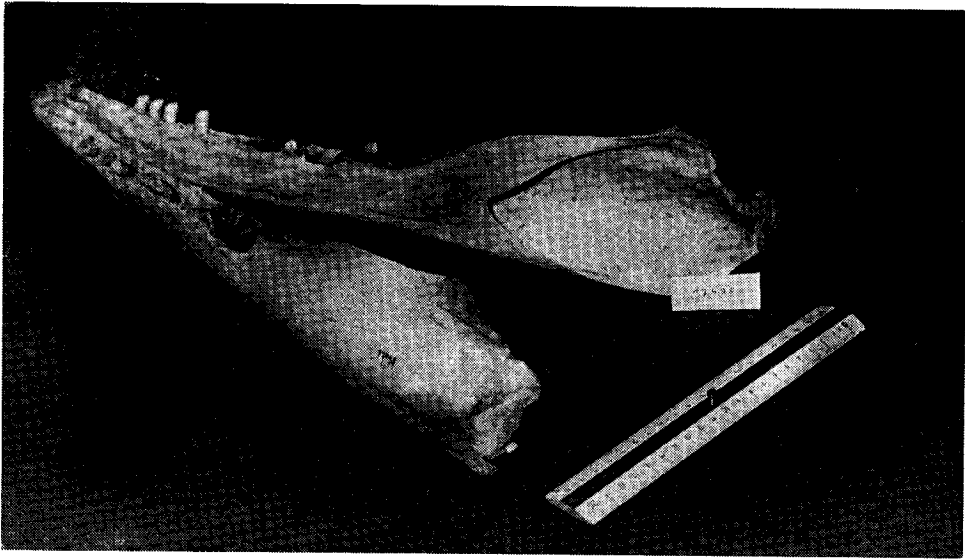


Figure 2

Mandible of an old male bottle-nosed dolphin, 3.10 m long, stranded on the Belgian coast in August 1963. Most of its teeth are lacking and bone erosion has occurred at two places. The condylus of the left side is broken off.

Another example is that of a specimen, 2.90 m long, nearly full-grown, but still having a few free epiphyses of the vertebrae. It was caught in 1960 as a straggler in the Scheldt-river far from sea. Its teeth show a similar abrasion as in the previous specimen, but all are still present.

It is clear that further abrasion of the teeth will reach the pulp cavity and open the way for infections. In many cases such an infection has already taken place before abrasion has gone that far, because teeth may be broken off. As an example of such early tooth fractures one may cite a 2.39 m specimen that had lived for five years in the Antwerp Zoo and was probably some 8 years old (the dolphin "Gibi"): although it still had nearly conical teeth, the 2nd, 3rd and 4th teeth of the left upper row were broken, even so badly that in the 2nd and 4th teeth the pulp cavity was open. In another not full-grown specimen, 2.65 m long, that had lived one and half a year in the Zoo, several teeth were lacking and one tooth was partly broken off, things that probably had happened before the animal had entered the delphinarium.

In all the full-grown specimens of over 3 m, stranded at the Belgian coast or found in the river as stragglers, many teeth are broken or lacking (Fig. 2). In two of them hardly any teeth are left, in another one there even are no teeth left. Many of the remaining teeth of those old specimens are broken or very worn. When teeth are lacking the open alveoli get invaded by bony tissue and the alveolar borders may become flattened. When a complete row of teeth is lacking, the alveolar row may get the shape of a furrow, in which the individual alveoli are hardly recognizable.

In several of these cases alveolar inflammation has occurred and abscesses have appeared. As a result, the surrounding bony tissue of the maxilla or mandible has been eroded, so that pits or even perforations are existing in the bone (Fig. 2). In two cases

new formation of bone took place, in one case in the form of a lump on the mandible, in another case as a bony bridge on the inner side of the mandible.

One may wonder how these toothless or nearly toothless dolphins may have been able to catch their food, the more because the slippery fishes are not easily kept when the conical teeth are lacking (°). One can only guess that inflammations and abscesses have caused a lot of trouble to the animals. No wonder that these dolphins finally get exhausted by food shortage and strand some day on the beach or die somewhere in the sea.

A most remarkable case of feeding problems is that of an old male of 3.19 m found in August 1963 on the Belgian coast. The articular process of its left mandible was broken off (Fig. 2) and had undergone a coalescence with the condylar cavity of the temporal bone. The state of this coalescence shows that the mandible fracture was not a recent one but at least several months old. It is difficult to imagine how the accident happened, but it is even more difficult to understand how the animal managed to survive. Opening of the mouth has probably been a very painful experience for this animal, that missed already most of its teeth.

VAN BREE and DUGUY (1970) report a case of a median fracture of the left mandible in a bottle-nosed dolphin, followed by the appearance of a pseudo-arthrosis. They also report a case of a fracture of the anterior part of the mandible in a harbour porpoise, *Phocoena phocoena*; they agree that in the latter species such fractures are very rare, because this is the only one known out of a large number. In our own material of the harbour porpoise, consisting of 18 skeletons, most of them from old specimens that washed ashore, we do not find examples of mandible affection, nor of tooth infection, nor of tooth loss, as seen so frequently in the bottle-nosed dolphin. In several other species of Odontocetes tooth infections may occur, and they have been described recently in the white-beaked dolphin (DE SMET, 1972), but they do not seem to be as common as they are in the bottle-nosed dolphin.

So it may be concluded that tooth lesions are more common in the bottle-nosed dolphin than in other species of cetaceans. They may be one of the major reasons of illness in this species, not only in nature but also in captive specimens.

Broken ribs and broken apophyses.

Broken ribs are not rare in cetaceans. Mostly it concerns the posterior ribs, as SLIJPER (1931 and 1936) believed.

Out of the eight wild specimens of the Brussels museum four have had a broken rib at some moment of their life. One of them is the mounted specimen: its left 12th rib shows a callus that is reminiscent of a fracture many years ago. In another specimen, an old male stranded in 1935, the 8th rib of the left side shows a callus of the same order. In an old male from 1963 the 10th rib of the left side is in such a condition. The old female that had entered the Scheldt-river in 1934, and whose skeleton has already been described by SLIJPER (1938), is the most interesting example: the 3rd, 4th, 5th and 6th rib of the right side are broken and partially healed with the formation of calluses. There are two levels of breaking, a lower one affecting the 3rd and 4th rib and a higher one affecting the 4th, 5th and 6th rib. At the lower level the distal

(°) In the stomach of an old, nearly toothless dolphin, caught in the Scheldt-river on Dutch territory in 1976, only shrimps were found.

fragment of the 4th rib has been displaced anteriorly before healing, so that it is not in line with the other part.

Although the thick blubber layer surely must be a good absorber against shocks from outside, and although dolphins live in water, ribfractures seem to occur quite frequently, half of these wild specimens having suffered from them. But also half of the four delphinarium specimens of the same collection show broken ribs. In one of them, "Siska", the 3rd, 4th and 5th rib of the right side are broken and only the 3rd shows a slight healing. In another one, "Gibi", the 2nd to 5th rib of the left side and the 3rd sternal rib of the same side are broken, all of them showing slight healing by the formation of new bone near the fracture.

None of the latter specimens has been observed to be the victim of severe crashes between animals, nor had any of them a big accident during performances. Judging from the state of healing, the fractures must have occurred only a few weeks before death, and they possibly have caused or aggravated the lung diseases the dolphins are so often suffering from.

It is important to point out that such fractures are generally not recognized during general autopsy. Only in one delphinarium specimen, whose skeleton has not been conserved for the study collection, broken ribs were recognized because they clearly protruded into the thoracic cavity. All these findings give the impression that rib fractures are more common in delphinarium specimens than often is believed; they should receive attention during autopsies.

Another important fact is that in the wild specimens the broken ribs nicely heal. In the delphinarium specimens, however, healing does not seem to follow that easily. One may suppose that the jumps during performances, the swimming in a limited space and occasional beaching during performances or during examination are not favourable for healing. If, after an accident, rib fractures can be suspected, it seems to be recommendable not to take the animal out of the water for some weeks. Their body-weight, no longer sustained by the surrounding water, could push the rib into the lungs and cause pulmonary lesions.

The old wild specimen with the many broken ribs also shows broken but completely healed lateral apophyses of two lumbar vertebrae. Another wild specimen, caught in the river in 1960, had several broken and healed neural spines in the lumbar region. SLIJPER (1931 and 1936) reports several cases of broken apophyses in other cetacean species. Although such fractures may be quite common, they heal easily and apparently do not cause much harm to the animal.

Bone affections

The five stranded and the two river specimens of the present material all show affections of the skeleton to some degree. This does not necessarily imply that all older animals in nature suffer from such diseases. More probably such diseases are among the factors that make many specimens suffering and badly adapted so that they finish their lives on the beach or in a river. Nevertheless, some affections seem to be very common in the bottle-nosed dolphin; even in quite young specimens slight attacks of them can appear.

One of the most common forms is periosteitis. It is not so much to be considered as a disease, but more as a phenomenon. It leads to the appearance of exostotic humps or hooks on the bone surface, predominantly on the spots where the tendons are attached and muscular traction is intense. The periosteitis may be of local appearance

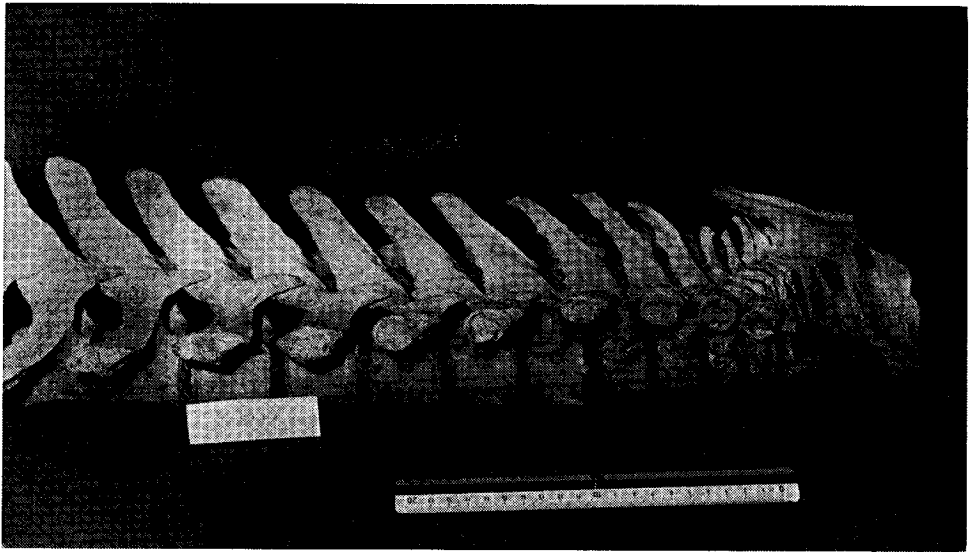


Figure 3
Cervical (left) and thoracic (middle and right) vertebrae of an old bottle-nosed dolphin, about 3 m long, stranded on the Belgian coast in 1937. Locally the surface of the vertebrae is very rough. Periosteitic exostoses are apparent on several neural spines.

or it may be spread over a large part of the skeleton. It mostly appears on the vertebrae (Fig. 3). But it may also occur on the ribs, the sternum, the scapulae and the chevron-bones. It is quite rare on the head and on the bones of the flippers. Generally periosteitis causes little harm to the subject. It may appear early in life and also in delphinarium specimens: three out of the four delphinarium skeletons show slight local exostoses, especially at the underside of the first cervical vertebrae.

Periosteitic and other exostoses become harmful when they appear on articular places. In two of the wild specimens they exist on the occipital condyluses (Fig. 1). Such exostoses are hindering the movements of head and perhaps make these painful. In both specimens the bony crests of the head are very pronounced, narrowing the space between the occipital condylus and the temporal groove (Fig. 1). In one specimen the exostoses are even entering into the occipital foramen (Fig. 1): they must have hindered the blood circulation in the rete mirabile and may have even pressed on the neural cord.

In the same specimen, being the old female river-straggler with the broken ribs and the very worn-off teeth, bony tissue is partially closing several foramina of the head: the internal foramen of the acoustic nerve of the right side, the optic canal of that same side and the oval foramen of the left side. It can not be excluded that in the animal the right side was partially or completely deaf and blind and that the left mandibular nerve could not transmit the movement orders to the lower jaw.

In two specimens severe forms of rheumatic illnesses are existing, resembling the ankylosing vertebral hyperostosis found in the human. However, these cases are not as severe as described in the white-beaked dolphin (DE SMET, 1972). In one of the specimens they caused a coalenscence between the lateral apophyses of two of the vertebrae of the caudal region. In the other specimen, an animal washed ashore in

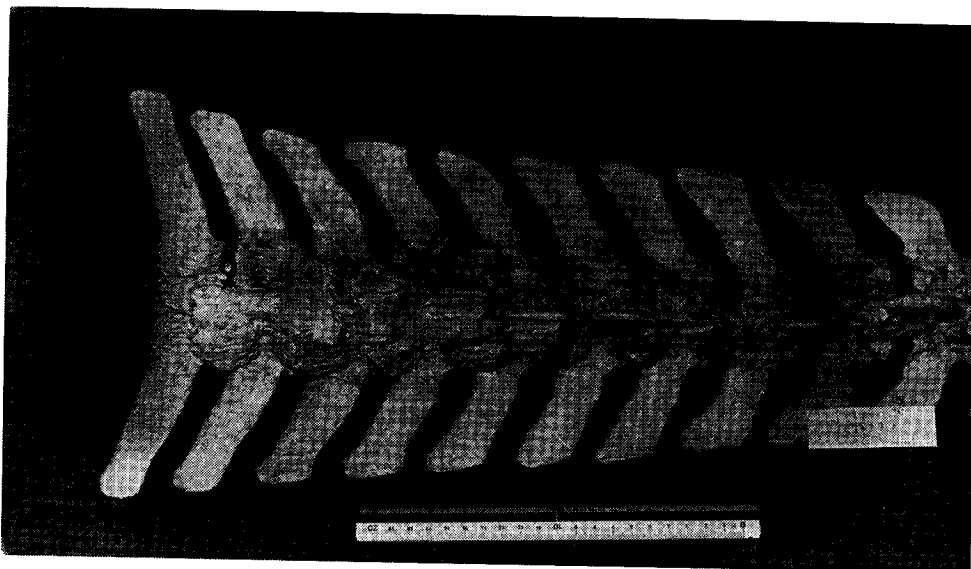


Figure 4

Ventral side of a series of vertebrae from the lumbo-sacral (left) and caudal (middle and right) region of the same specimen as in fig. 3. Spondylitic osteophytes are protruding from the bodies of several vertebrae, invading the chevron-bones or causing an ankylosis between neighbouring vertebrae.

1937, spondylitic osteophyses have caused the ankylosis of several vertebrae in different places of the lumbar and caudal region (Fig. 4). One of these osteophyses is quite voluminous and must have seriously hindered the movements of the ventral tail muscles and the course of the nerves and the blood-vessels. It also must have limited the movements of the vertebral column in this region, but, because the vertebral movements are not very extensive here, such osteophyses probably are not of great influence on the general ability of the animal. The narrowing of the neural canal in this region by osteophytes is also not important, because the neural cord does not extend so far backwards in the vertebral column.

Conclusions

In conclusion one may say that most of the stranded or river-dwelling bottle-nosed dolphins were old, diseased animals. Perhaps they suffered from a number of diseases, and the author regrets not to know more about their health-condition than what can be concluded from the skeletons. In any case, the skeletons reveal enough signs of suffering to make it understandable that the animals were incapable for the struggle for life. Periosteitic aspects are present in all of them and several forms of spondylitis are seen in two of them.

Broken ribs are common as well, something truly surprising for animals with such a fat-layer, living in the water, often far from rocky shores. Perhaps the most crucial causes for their suffering are tooth abrasion, tooth breaking and tooth loss; abscesses and bone perforations occur and later, when many teeth are lost, the animal is unable

to catch and hold its prey, and doomed to a gradual exhaustion that ends in death. Deaths in delphinaria usually have other causes than in nature. It is important, however, to draw attention to the facts that also in delphinarium specimens slight periosteitis occurs, that teeth may wear and break and that fractured ribs are more common than is usually believed. Factors to which not enough attention has been paid so far during autopsies.

References

- BREE P. J. H. van and R. DUGUY (1970). Sur quelques aberrations pathologiques chez les petits Cétacés. - Zool. Garten, 39, 11-15.
- BUCHANAN J. Y. (1910). The Oceanographical Museum at Monaco. - Nature, 85, 7.
- MONTAGU G. (1821). Description of a specimen of *Delphinus* which appears to be new. - Mem. Wernerian nat. Hist. Soc., 3, 75-82.
- RODE P. (1939). La collection de Cétacés du Musée Océanographique de Monaco. Notes ostéométriques. - Bull. Inst. Océan. Monaco, 780, 20 pp.
- SLIJPER E. J. (1931). Ueber Verletzungen und Erkrankungen der Wirbelsäule und Rippen bei den Cetaceen. - Anat. Anz., 71, 156-185.
- SLIJPER E. J. (1936). Die Cetaceen vergleichend-anatomisch. - Capita zool., VI + VII. Nijhoff, Den Haag, 590 pp.
- SLIJPER E. J. (1938). Die Sammlung rezenter Cetacea des Musée royal d'Histoire naturelle de Belgique. - Bull. Mus. r. Hist. nat. Belg., 14, nr. 10, 33 pp.
- SMET W. M. A. de (1972). Sur deux dauphins à bec blanc, *Lagenorhynchus albirostris* (GRAY), de la côte Belge. - Bull. Instr. r. Sci. nat. Belg., Biol., 48, nr. 10, 17 pp.
- SMET W. M. A. de (1974). Inventaris van de Walvisachtigen (Cetacea) van de Vlaamse kust en de Schelde. - Bull. Inst. r. Sci. nat. Belg., Biol., 50, nr. 1, 156 pp.
- — —