

Incidental predation by a largetooth cookiecutter shark on a Cuvier's beaked whale in Puerto Rico

José J. Pérez-Zayas¹, Antonio A. Mignucci-Giannoni¹, Gian M. Toyos-González²,
Raul J. Rosario-Delestre³ and Ernest H. Williams, Jr.⁴

Red Caribeña de Varamientos—Caribbean Stranding Network, PO Box 361715 San Juan,
Puerto Rico 00936

¹Caribbean Marine Mammal Laboratory, Department of Science and Technology, Universidad Metropolitana,
PO Box 21150 San Juan, Puerto Rico 00927

²School of Environmental Affairs, Universidad Metropolitana, PO Box 21150 San Juan, Puerto Rico, 00927

³Departamento de Ciencias Naturales, Universidad Interamericana de Puerto Rico, PO Box 191293 San Juan,
Puerto Rico 00919

⁴Department of Marine Sciences, University of Puerto Rico, PO Box 908 Lajas, Puerto Rico 00667

Abstract

Two species of cigar or cookiecutter sharks (*Isistius brasiliensis* and *I. plutodus*) are known to predate by causing crater wounds on pelagic fishes off Puerto Rico and in marine mammals in other parts of the world. No records exist for wounds caused by the largetooth cookiecutter shark (*I. plutodus*) in marine mammals, and furthermore, no records exist for the Caribbean of wounds inflicted on whales or dolphins by either of these sharks. We report the first record of cookiecutter shark predation in a stranded Cuvier's beaked whale (*Ziphius cavirostris*) from Puerto Rico. We attributed this wound to have been caused by a largetooth cookiecutter shark, based on its size and shape, in addition to the characteristic teeth markings creating pointed-grooves on the borders and the inside of the bite. The finding of a largetooth cookiecutter shark attack on this specimen is of particular interest since it is the first time we have observed this type of fresh wound in our study area. Cookiecutter shark wounds attributed to the widely-distributed cigar shark, have been reported in ten species of seals, whales, and dolphins. However, this is the first record of a largetooth cookiecutter shark wound on a cetacean.

Key words: Caribbean, *Isistius brasiliensis*, *Isistius plutodus*, *Ziphius cavirostris*, predation, cookiecutter shark, Cuvier's beaked whale.

Introduction

Two species of cigar or cookiecutter sharks (*Isistius brasiliensis* and *I. plutodus*) are known to predate by

causing crater wounds on pelagic fishes off Puerto Rico, such as Atlantic blue marlin (*Makaira nigricans*), dolphin fish (*Coryphaena hippurus*), yellowfin tuna (*Thunnus albacares*), albacore (*Thunnus alalunga*), and blackfin tuna (*Thunnus atlanticus*) (Williams & Bunkley-Williams, 1996). In other localities, the cosmopolitan cookiecutter shark (*I. brasiliensis*) has been suspected as responsible for wounds in marine mammals, especially cetaceans (Jones, 1971). No records exist for wounds caused by the largetooth cookiecutter shark (*I. plutodus*) in marine mammals, and furthermore, no records exist for the Caribbean of wounds inflicted on whales or dolphins by either of these sharks. We report the first record of cookiecutter shark predation in a Cuvier's beaked whale (*Ziphius cavirostris*) from Puerto Rico.

Case report

On 29 July 1998, an adult Cuvier's beaked whale stranded off Parque Colón, Aguadilla (18°24.9'N, 67°09.7'W), part of a mass stranding of five Cuvier's beaked whales. The whale, a male, measured 530 cm in length and was found in a fresh state of decomposition. This species is one of the most frequently stranded cetaceans in the North-eastern Caribbean and has been recorded during all months of the year (Mignucci-Giannoni, 1998), thus indicating their residency in this area. Upon external examination of the animal, we noticed on its right flank an oval-shaped crater wound some 21 cm caudolateral to the umbilicus (Fig. 1). The wound measured 6 cm in length and 3.5 cm in height. Its central depth was about 2 cm. By the characteristic

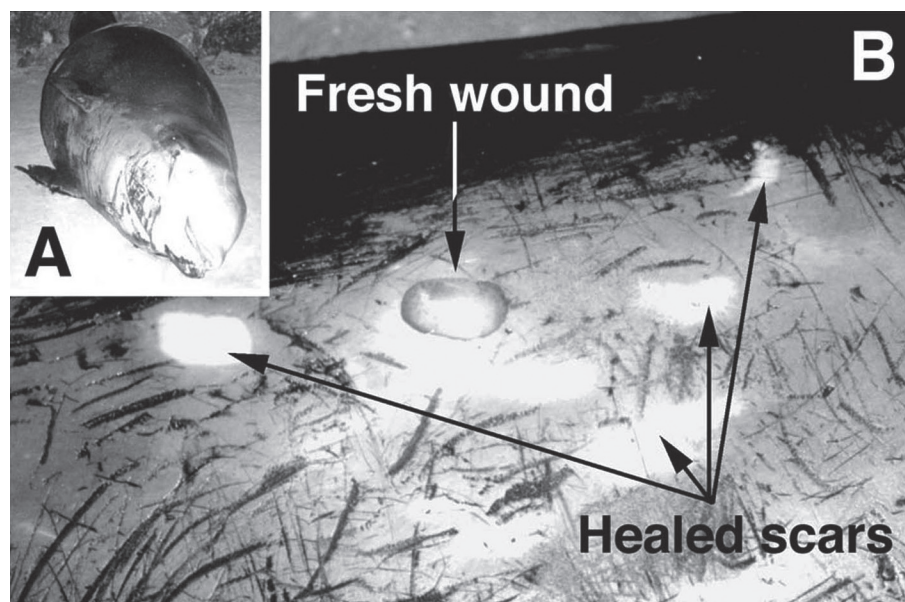


Figure 1. Male goosebeak whale stranded in Aguadilla, Puerto Rico (A). Evidence of largetooth cookiecutter shark attack to whale specimen, showing the fresh wound and healed scars (B).

dermal haemorrhage and the specimen's fresh state of decomposition, the wound appeared to have been made *ante-mortem*. No other fresh wounds were found on the carcass, although a number of healed oval-shaped scars were visible near the wound and genital area.

Compagno (1984) and Garrick & Springer (1964) described the predatory behavior for the *I. brasiliensis* as the shark clamps onto its prey's skin with its jaws and bites down with its sharp teeth on its lower jaw, twisting its body around and gouging out a plug-like piece of flesh. The shark then creates an oral suction with its thick fleshy lips, large tongue and strong throat muscles to suction the piece of flesh out of the prey's body. Williams & Bunkley-Williams (1996) described the wounds of *I. brasiliensis* as round-shaped with an interior spiral pattern of more than 15 groove teeth marks corresponding to the known tooth count on the species lower jaw, while those of *I. plutodus* as oval and elongated with an interior parallel pattern of about 13 groove teeth marks also corresponding to the numbers of species tooth count (Fig. 2). Thus, we attributed the wound observed on the Cuvier's beaked whale in Puerto Rico to have been caused by a largetooth cookiecutter shark, based on its size and shape, in addition to the characteristic teeth markings creating parallel grooves on the borders and the inside of the bite.

Discussion

The finding of a largetooth cookiecutter shark attack on this specimen is of particular interest since it is the first time we have observed this type of fresh wound in our study area, considering that we have tended over 130 marine mammal strandings in Puerto Rico and the Virgin Islands since 1985 (Mignucci-Giannoni, 1996). During these strandings, we have seen shark attacks on carcasses of sperm whales (*Physeter macrocephalus*), humpback whales (*Megaptera novaeangliae*), and Cuvier's beaked whales, especially of the tiger sharks (*Galeocerdo cuvieri*), as well as healed scars of cookiecutter sharks, but we have not observed fresh small cookiecutter-type wounds. Cookiecutter shark wounds attributed to the widely-distributed *Isistius brasiliensis*, have been reported in Guadalupe fur seals (*Arctocephalus townsendi*) (Gallo-Reynoso & Figueroa-Carenza, 1992), northern elephant seals (*Mirounga angustirostris*) (Le Boeuf *et al.*, 1987), sperm whales (Rice, 1989), blue whales (*Balaenoptera musculus*) and fin whales (*Balaenoptera physalus*) (Mackintosh & Wheeler, 1929), Fraser's dolphins (*Lagenodelphis hosei*) (Perrin *et al.*, 1973), melonhead whales (*Peponocephala electra*) (Best & Shaughnessy, 1981), harbor porpoises (*Phocoena phocoena*) (van Utrecht, 1959), beaked whales (*Mesoplodon* spp.) and Cuvier's

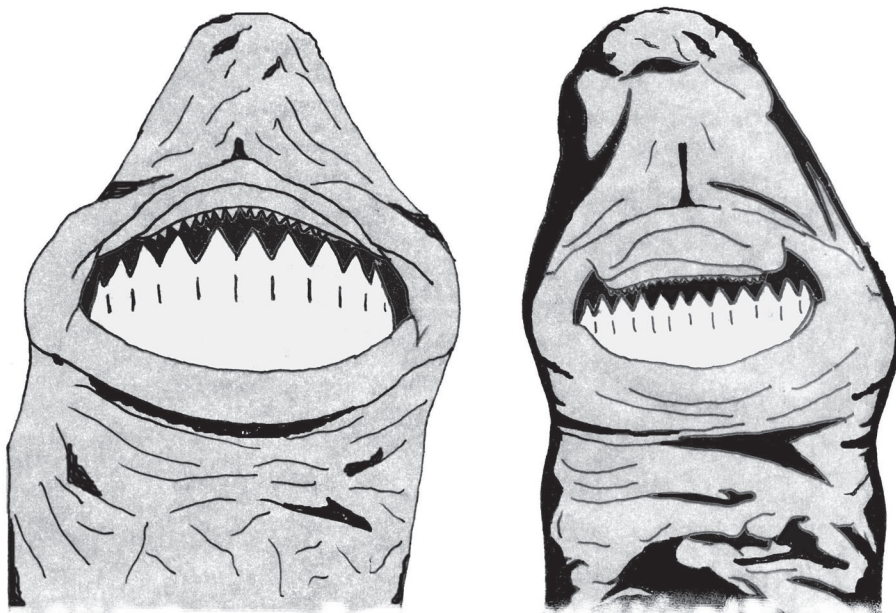


Figure 2. Composite illustration showing the mouth and teeth of the two species of cookiecutter sharks, *Isistius plotodus* (left) and *Isistius brasiliensis* (right).

beaked whales (Mead *et al.*, 1982; Heyning, 1989). This is also the first record of a largetooth cookiecutter shark wound on a cetacean.

Acknowledgments

The carcass was salvaged under a letter of authorization from NOAA's National Marine Fisheries Service Protected Species Management Branch and a cooperative agreement with Puerto Rico's Department of Natural and Environmental Resources. We gratefully acknowledge the assistance of Caribbean Stranding Network participants and volunteers in tending to the mass stranding, especially M. M. Alsina, O. Alsina, V. I. Ayala, M. A. Cardona, B. Carrasquillo, G. Delgado, L. E. Figueroa, K. V. Hall, N. Miranda, D. M. Mora, M. F. Muñoz, J. Pérez, M. Ramirez, E. Rivera, and M. Vargas. This research was funded in part by the National Science Foundation's Model Institute of Excellence (MIE) Project and a grant from the Commonwealth of Puerto Rico Legislature.

Literature Cited

- Best, P. B. & Shaughnessy P. D. (1981) First records of the melon-headed whale *Peponocephala electra* from South Africa. *Annals of the South African Museum* **83**, 33–47.
- Compagno, L. J. V. (1984) *FAO Species Catalogue*. Vol. 4, Sharks of the World. An annotated and illustrated catalogue of shark species known to date. Part 1—Hexanchiformes to Lamniformes: viii, 1–250.
- Gallo-Reynoso, J. P. & Figueroa-Carenza A. L. (1992) A cookiecutter shark wound on a Guadalupe fur seal male. *Marine Mammal Science* **8**, 428–430.
- Garrick, J. A. F & Springer, S. (1964) *Isistius plutodus*, a new squaloid shark from the Gulf of Mexico. *Copeia* (4): 678–682.
- Heyning, J. E. (1989) Curvier's beaked whales—*Ziphius cavirostris* G. Cuvier 1823. In: S. H. Ridgway & R. Harrison (eds.) *Handbook of Marine Mammals*, Volume 4: *River dolphins and the larger toothed whales*, pp. 289–308. Academic Press, San Diego.
- Jones, E. C. (1971) *Isistius brasiliensis*, a squaloid shark, the probable cause of crater wounds on fishes and cetaceans. *Fishery Bulletin* **69**, 791–798.
- Le Boeuf, B. J., McCosker J. E. & Hewitt, J. (1987) Crater wounds on northern elephant seals: the cookiecutter shark strikes again. *Fishery Bulletin* **85**, 387–392.
- Mackintosh, N. A. & Wheeler J. F. G. (1929) Southern blue and fin whales. *Discovery Reports* **1**, 257–540.
- Mead, J. G., Walker W. A. & Houck W. J. (1982) Biological observations on *Mesoplodon carlhubbsi* (Cetacea: Ziphiidae). *Smithsonian Contributions to Zoology* **344**, 1–25.
- Mignucci-Giannoni, A. A. (1996) Marine mammals strandings in Puerto Rico and the United States and British Virgin Islands. Doctoral dissertation, University of Puerto Rico, 247 pp.
- Mignucci-Giannoni, A. A. (1998) Zoogeography of cetaceans off Puerto Rico and the Virgin Islands. *Caribbean Journal of Science* **34**, 173–190.
- Perrin, W. F., Best P. B., Dawbin W. H., Balcomb K. C., Gambell R. & Ross G. J. B. (1973) Rediscovery of Fraser's dolphin *Lagenodelphis hosei*. *Nature* **241**, 345–350.

- Rice, D. W. (1989) Sperm whale—*Physeter macrocephalus* Linnaeus 1758. In: S. H. Ridgway & R. Harrison (eds.) *Handbook of Marine Mammals*, Volume 4: *River dolphins and the larger toothed whales*, pp. 177–233. Academic Press, San Diego.
- Utrecht, W. L. van. (1959) Wounds and scars on the skin of the common porpoise, *Phocoena phocoena* (L.). *Mammalia* **23**, 100–122.
- Williams Jr., E. H. & Bunkley-Williams, L. (1996) Parasites of offshore big game fishes of Puerto Rico and the western Atlantic. Puerto Rico Department of Natural and Environmental Resources and University of Puerto Rico, Mayagüez, p. 382.