Aquatic Mammals 1990, **16.3,** 101–119

The anatomy of the Walrus head (*Odobenus rosmarus*). Part 1: The skull

R. A. Kastelein and N. M. Gerrits*

Harderwijk Marine Mammal Park, Strandboulevard-oost 1, 3841 AB Harderwijk, Holland
**Anatomy Department, Erasmus University, P.O. Box 1738, 3000 DR Rotterdam, Holland*

Figure 1. Pacific Walruses on an ice-floe. Note the animal on the right which is using its tusks to haul out (Photo: Mike Jones).

Summary

This report describes the cranial bones of the Walrus and discusses their ecological significance for hauling out, feeding, and accommodation of the sensory organs. Age related changes in skull shape are observed.

Key words: *Odobenus rosmarus*, skull, feeding, hauling out.

Introduction

The shape of the Walrus skull differs strongly from that of other pinnipeds. Most of the differences are related to the feeding technique of excavation and processing of benthic prey (Oliver *et al.*, 1983; Kastelein & Mosterd, 1989), or to the development of the large tusks. These tusks are present in both sexes, and are used, among other things, for hauling out (Fay, 1981; Fig. 1).

Table 1. Information on the Walrus skulls used

Sub-species	Sex	Age	Origin	Storage	Code
rosmarus	—	Foetus	Greenland, Denmark	Cambridge	K7503
divergens	M	14 mnths	Wrangel Isl., USSR	Leiden	OrZH008
divergens	M	6 yrs	Wrangel Isl., USSR	Utrecht	OrZH005
divergens	M	30+ yrs	Fullerton, Alaska	Cambridge	K7561

Notwithstanding the interesting shape of the cranial bones of the Walrus, only few descriptions exist, of which most are either not detailed, or do not cover the complete skull. Allan (1880) described individual, sub-species, sexual and age related skull differences. A more recent description of skull sexual dimorphism was given by Mohr (1942). The particular features of the dentition were described by Cobb (1933) and King (1964). Fay (1981) gave a general description of the skull of an old Pacific Walrus, and showed photographs of its dorsal, ventral and lateral aspects. Fay (1982) described the dentition in detail and showed photographs of the lateral side of Pacific Walruses from 0 to 3 years of age. Fossil skulls have been described by Repenning & Tedford (1977) and by Bosscha Erdbrink & van Bree (1986).

This is the first part in a series of articles on the anatomy of the Walrus head. The objective of this study (part 1) is to give a description of the principal features of the skull, and to provide a framework for future descriptions of the soft tissues of the head. The observations will be discussed in a functional context.

Materials and methods

A large number of skulls were studied from the collections of the Natural History Museum of Leiden, Holland, the Museum of Zoology in Cambridge, UK, and the Veterinary Faculty of the University of Utrecht, Holland. The descriptions are based on the skulls of 3 male Pacific Walruses (*Odobenus rosmarus divergens*) and one Atlantic Walrus foetus (*Odobenus rosmarus rosmarus*) (Table 1).

The relation between the skull and the soft tissues was studied using slices of a complete Walrus head. The head of an approximately 8-year-old female Atlantic Walrus (*Odobenus rosmarus rosmarus*, code: KFHB88♯19) was obtained from Eskimos from the Hudson Bay area, Canada, in June 1988. The head was frozen immediately after death and was later mounted upside-down on a wooden board by means of straps. The tusks were removed from just below the gums. The frozen head was cut in 28 approximately 1 cm thick transverse sections with a band saw. Before each slice was removed it was labelled and a photograph was taken from the side of the head with a 2 cm grid in the background. Each slice was washed, photographed from both sides against a 2 cm grid background and stored in fixative.

Results

The following description is based on the skull of a 6-year-old male Pacific Walrus (OrZH005 in Table 1) in which the clearly visible sutures enabled the identification of the individual bones (Figs 3c, 4c, 5c, 6c, 7c, 9 and 10). Because this animal was fed fish at the Harderwijk park from the age of 1 year, the teeth are not as worn as they would be in animals of the same age in the wild. One should keep in mind that a wide range of individual variation occurs in this species, which is sufficiently evident from an examination of even a limited number of skulls. This was already noted by Fremerij (1831), Allan (1880) and Mohr (1942).

The skull of an adult Walrus is unusually heavily built. In dorsal view it is diabolo-shaped. The narrow interorbital region connects the facial and cerebral divisions of the skull, the development of which is dominated by their different functions.

1. Facial skull

The large tusks dominate the development of the viscerocranium.

Maxilla: The maxilla is exceptionally large, to accommodate the tusks, which are the upper canines (Fig. 2). The infraorbital foremen of the zygomatic process of the maxilla is very large (Fig. 10). The palatine process is arched and 2 pterygo-palatine canals have their aperture in it. The ventrorostral part of the maxilla contains many foramina for vessels and nerves leading to the tusk roots (Figs 3c, 4c, 5c, 6c and 10).

Premaxilla: The premaxillae are as strongly developed as the maxillary bones. The infranasal section has a long vertical extent, adding to the flattened rostral surface of the skull. The premaxillae are separated by a wide fissure and only firmly connected at the anterior nasal spine (Fig. 6c).

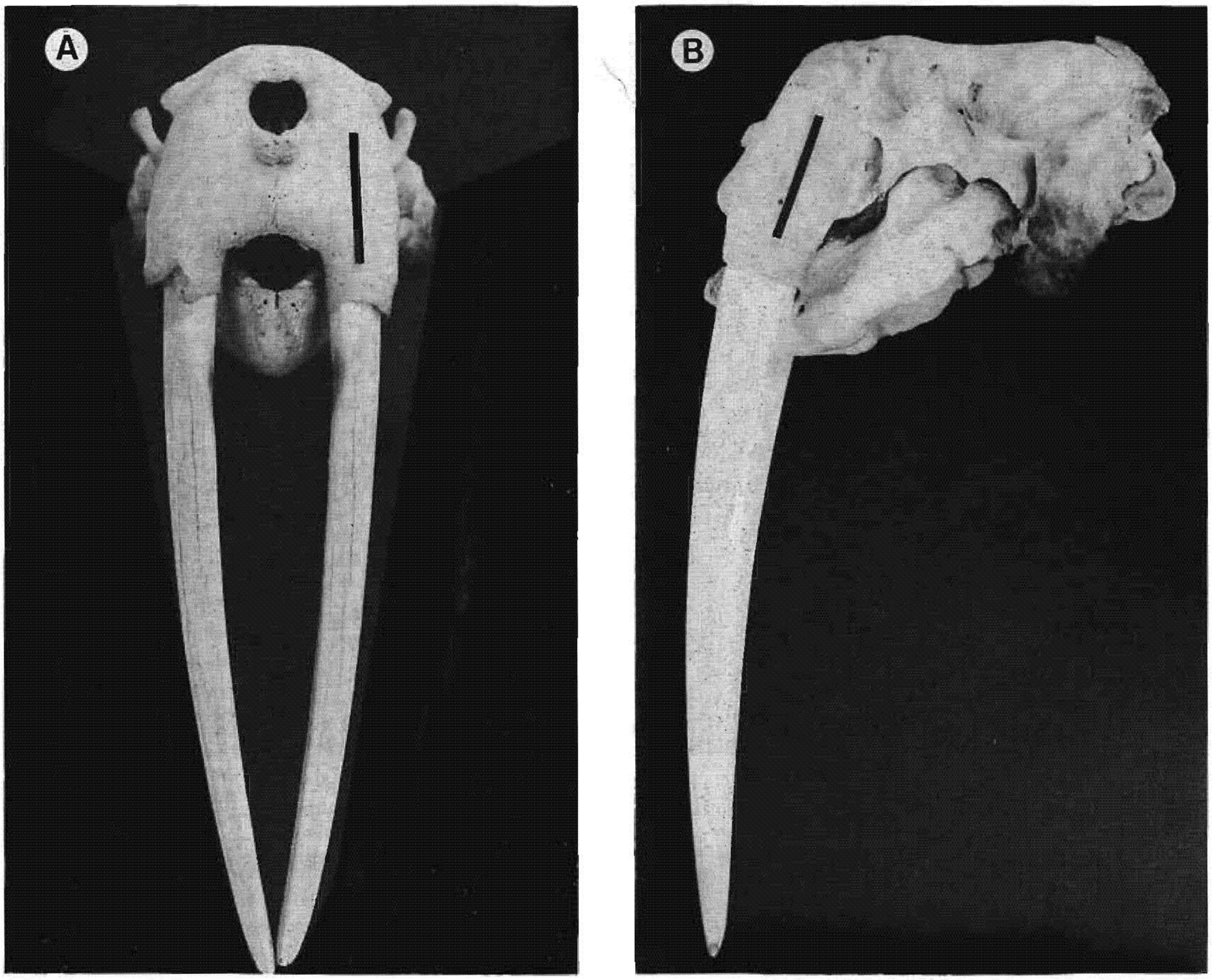

Figure 2. Rostral (A) and lateral view (B) of the skull of a 30+-year-old male Pacific Walrus (K7561). The bar indicates 10 cm.

Nasal: The nasal bones are rectangular in dorsal view, and are fully ankylosed with the maxillary bones (Figs 4c and 6c).

Palatine: In the caudal direction the palatine bones follow the curvature of the roof of the mouth cavity. The dorsal aspect of the lateral palatine lamina encircles the ventral half of the very large, round, sphenopalatine foramen. The upper half of this foramen is bordered by the sphenoid and frontal bones (Figs 5c and 10).

2. Central bones

The relatively light central bones form a connection between the facial skull and the cerebral skull, which are relatively heavily built.

Frontal: The frontal bones have shifted towards the rostrum, are to a large extent incorporated in the viscerocranium, and participate only minimally in the neurocranium. The broad fissure between the maxillae and the frontal bones is perpendicular to the longitudinal axis of the skull. Laterally the maxilla and frontal bones protrude to form the antorbital process. On the dorsal aspect of the skull, the frontal bones have a long caudal extension. The Walrus has no supraorbital process (Figs 3c and 4c).

Jugal: Rostrally the jugal bone is connected to the zygomatic process of the maxilla. Caudally it is separated from the zygomatic process of the temporal bone by 2–3 mm thick cartilage (which will be referred to as the zygomatic cartilage). This zygomatic cartilage appears to be continuous with the cartilagenous lining of the mandibular fossa. The postorbital process of the jugal bone is well developed and adds to the function of the zygomatic arch in protecting the eye (Figs 3c, 4c, 5c and 10).

Sphenoid: The ventral aspect of the sphenoid bone is characterized by a thick medial pterygoid process with an elongated and angular hamulus, which is extremely thick (Figs 5c and 10). Lateral to the medial pterygoid process the sphenoid has 3 foramina, a small oval foramen, a spinous foramen and rostrally an anterior alar foramen through which the

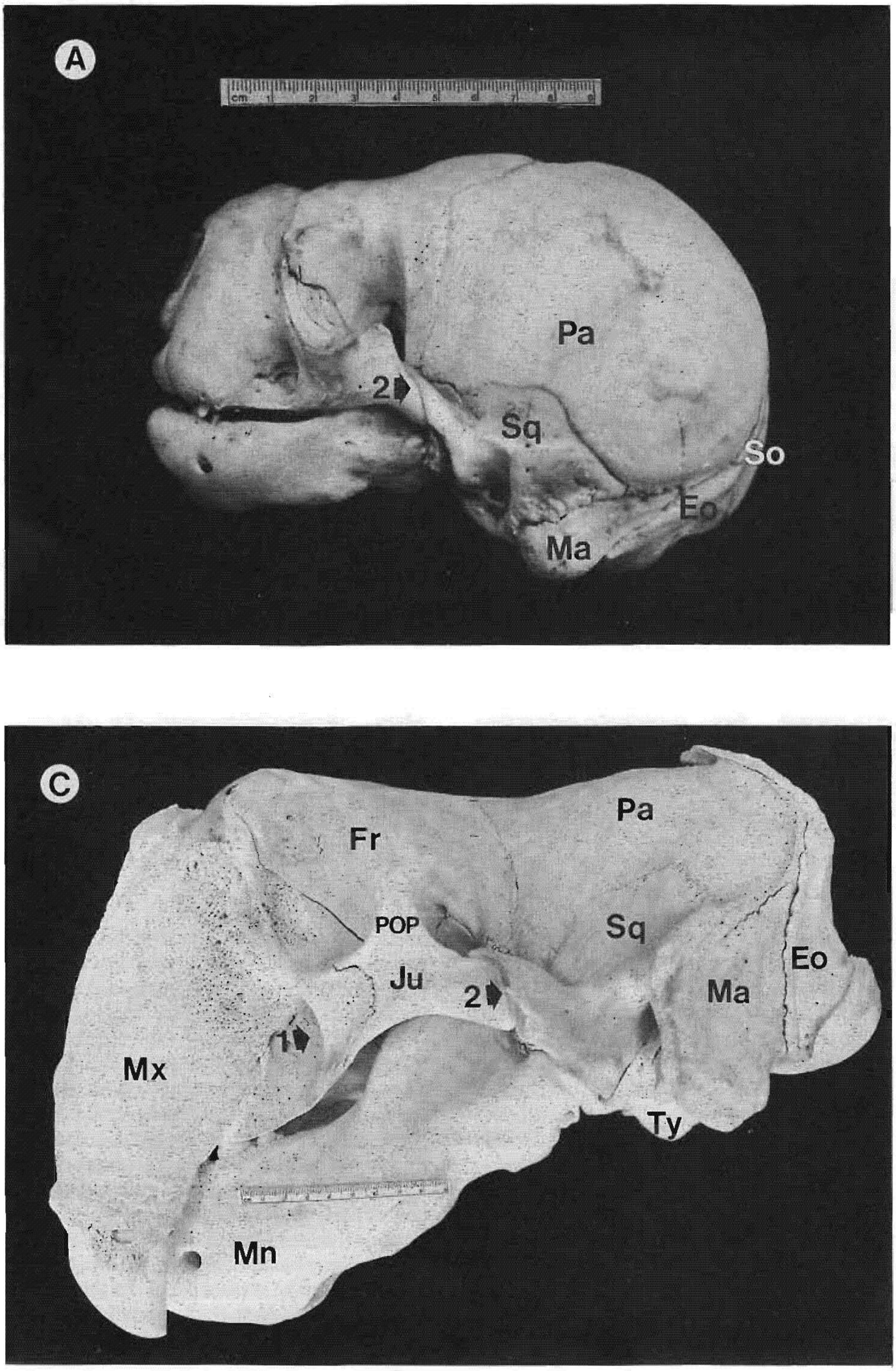

Figure 3. Lateral view of the skulls of: an Atlantic Walrus foetus (A), a 14-month-old male Pacific Walrus (B), a 6-year-old male Pacific Walrus (C), and a 30+-year-old male Pacific Walrus (D). Bones: Mx = Maxilla; Fr = Frontal; Pa = Parietal; Sq = Squamosal; Ju = Jugal; Eo = Exoccipital; Ty = Tympanic; Ma = Mastoid;

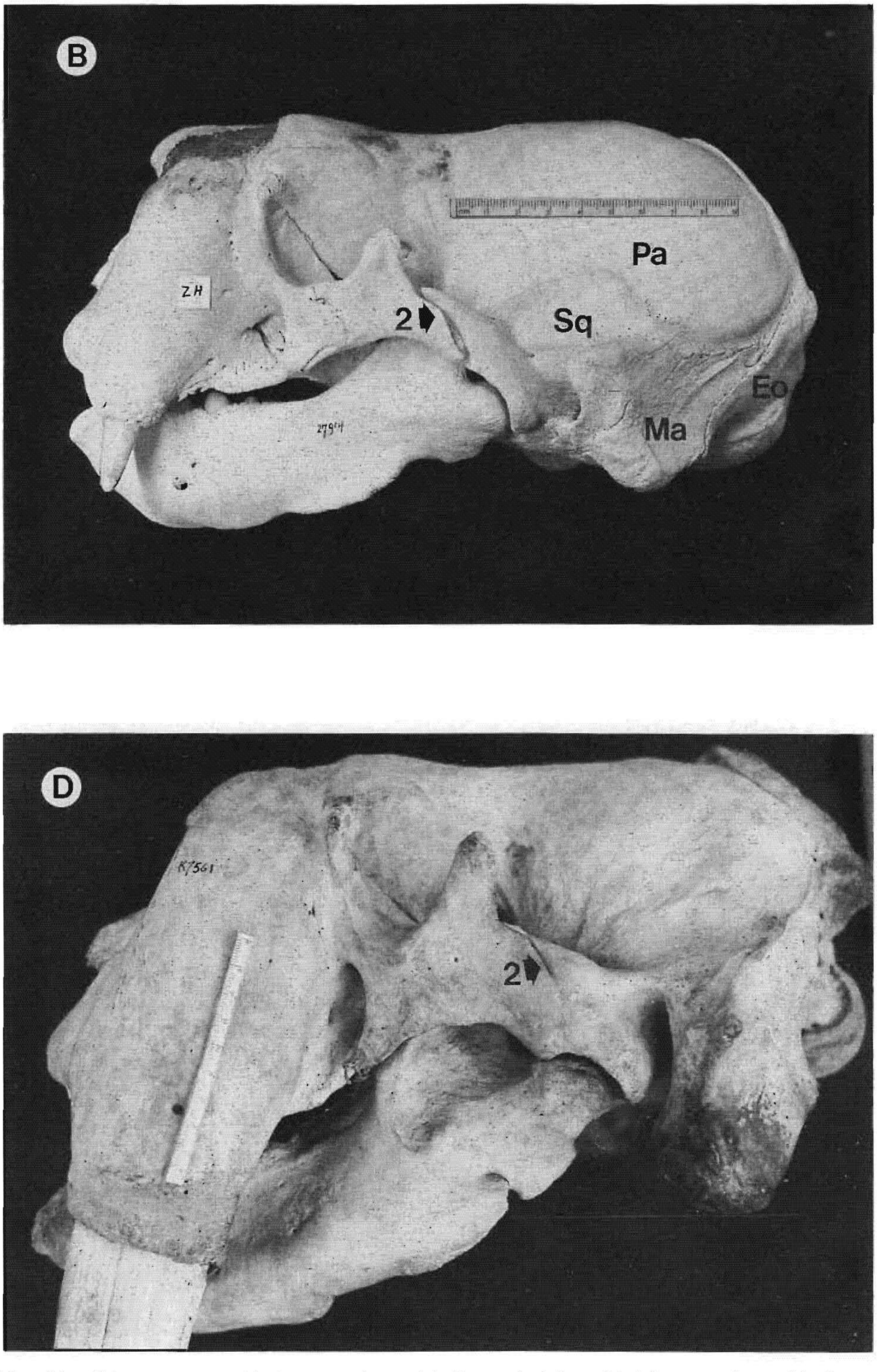

Mn = Mandible; pop = postorbital process. Arrow 1 indicates the infra-orbital foramen. Arrow 2 indicates the suture that was filled with zygomatic cartilage.

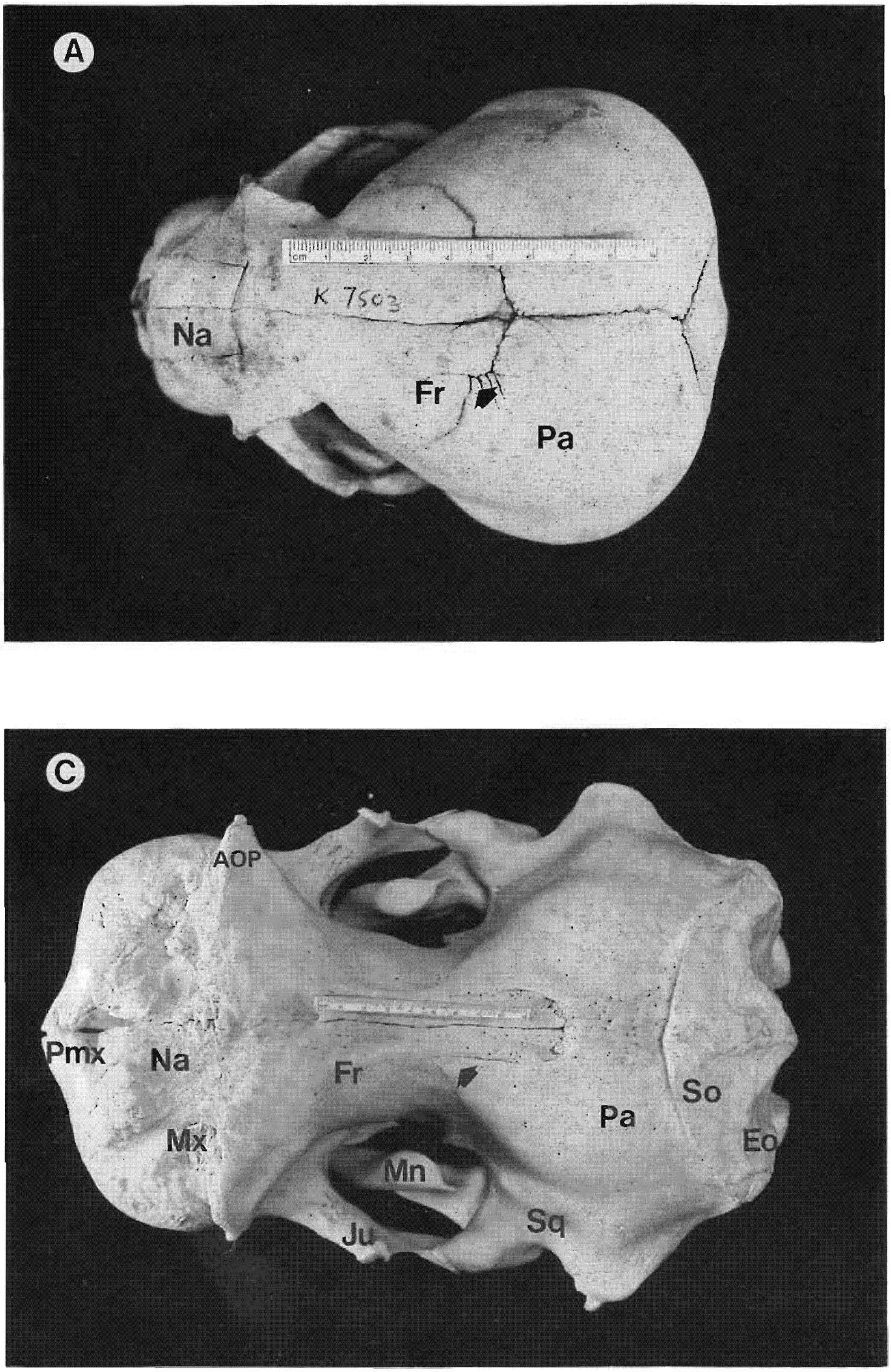

Figure 4. Dorsal view of the skulls of: an Atlantic Walrus foetus (A), a 14-month-old male Pacific Walrus (B), a 6-year-old male Pacific Walrus (C), and a 30+-year-old male Pacific Walrus (D). Bones: Pmx = Premaxilla; Mx = Maxilla; Na = Nasal; Fr = Frontal; Pa = Parietal; Sq = Squamosal; Ju = Jugal; So = Supraoccipital;

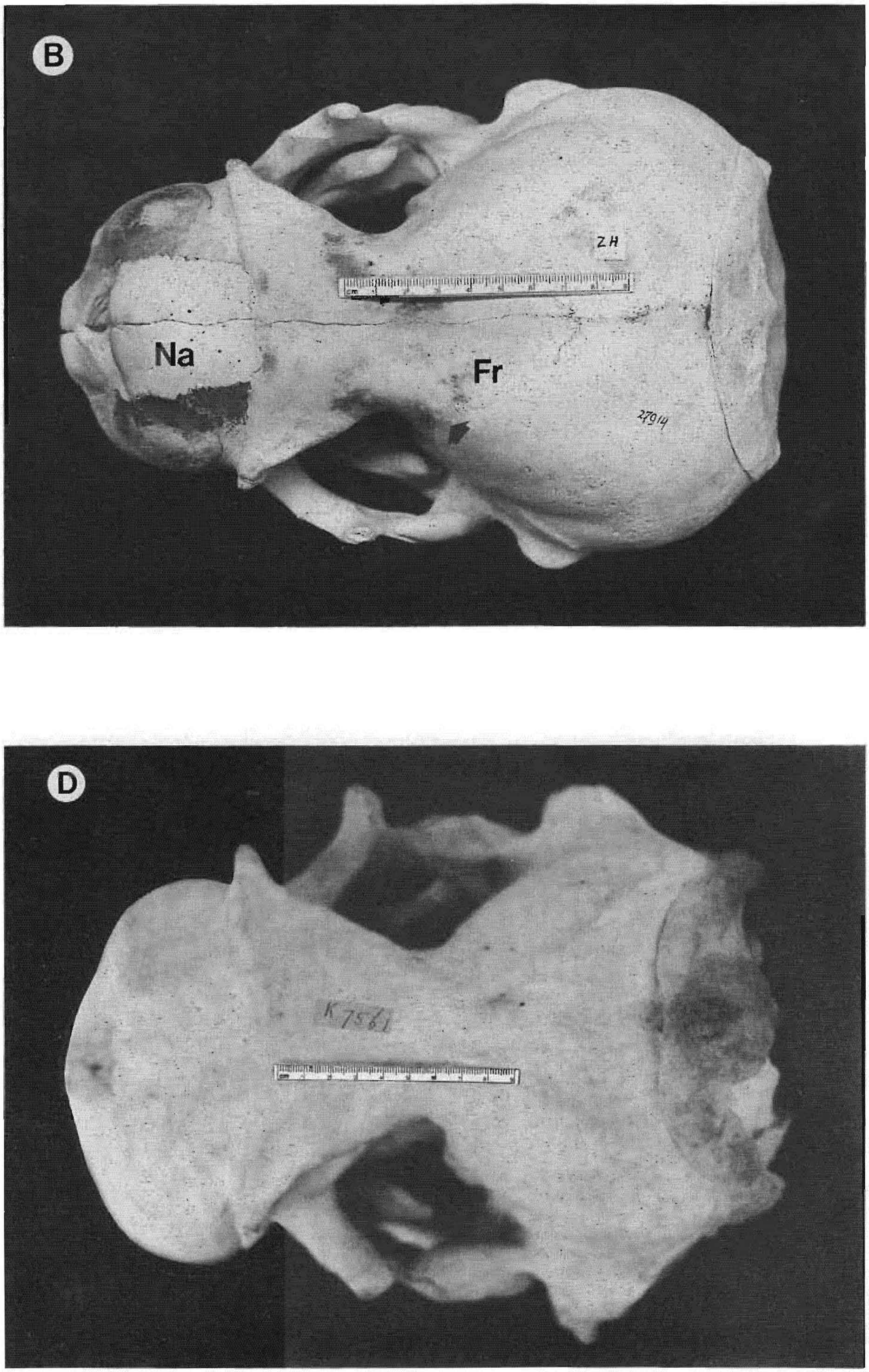

Eo = Exoccipital; Mn = Mandible; aop = antorbital process. The arrow indicates the anterior projection of the parietal bone.

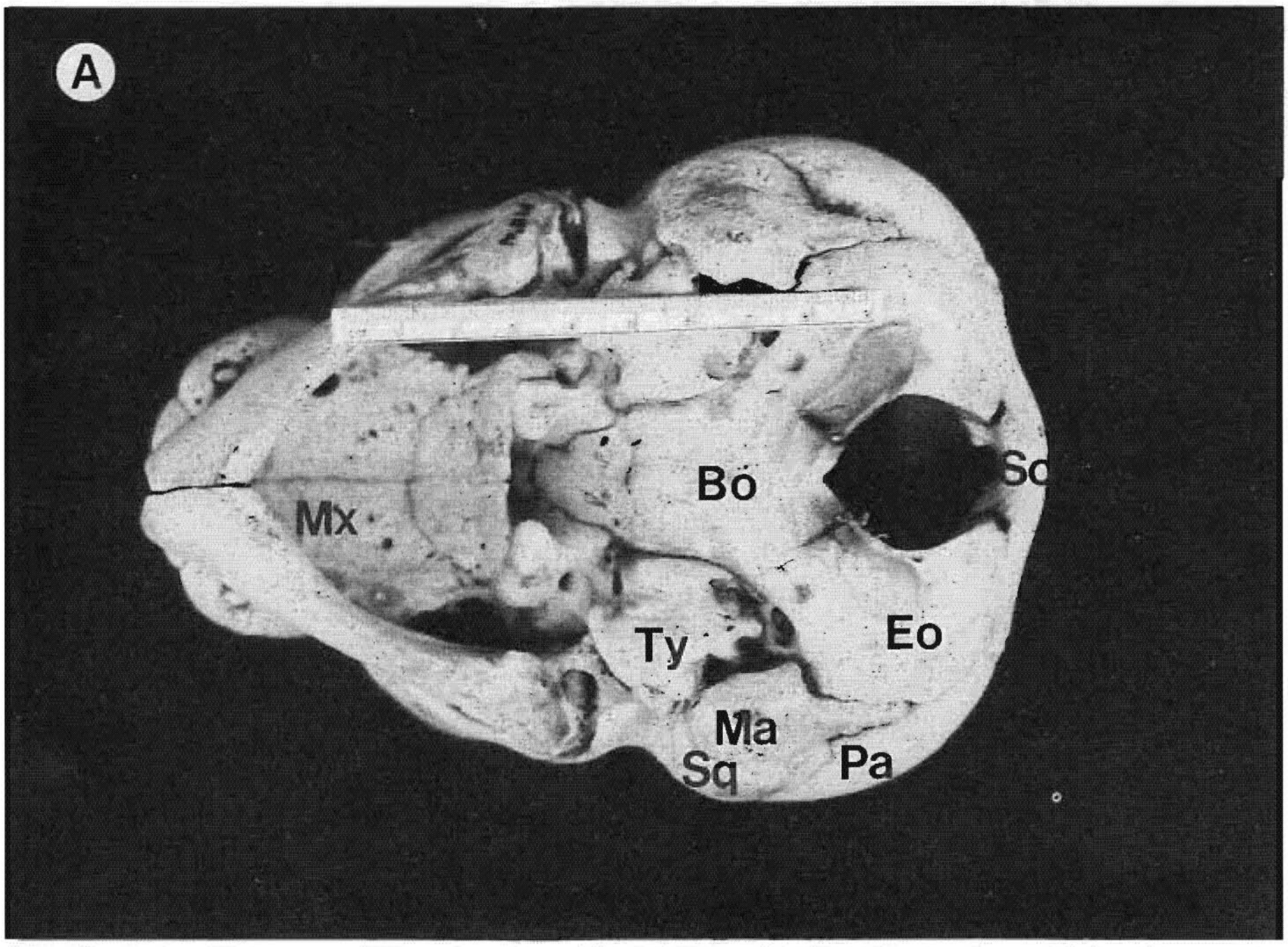

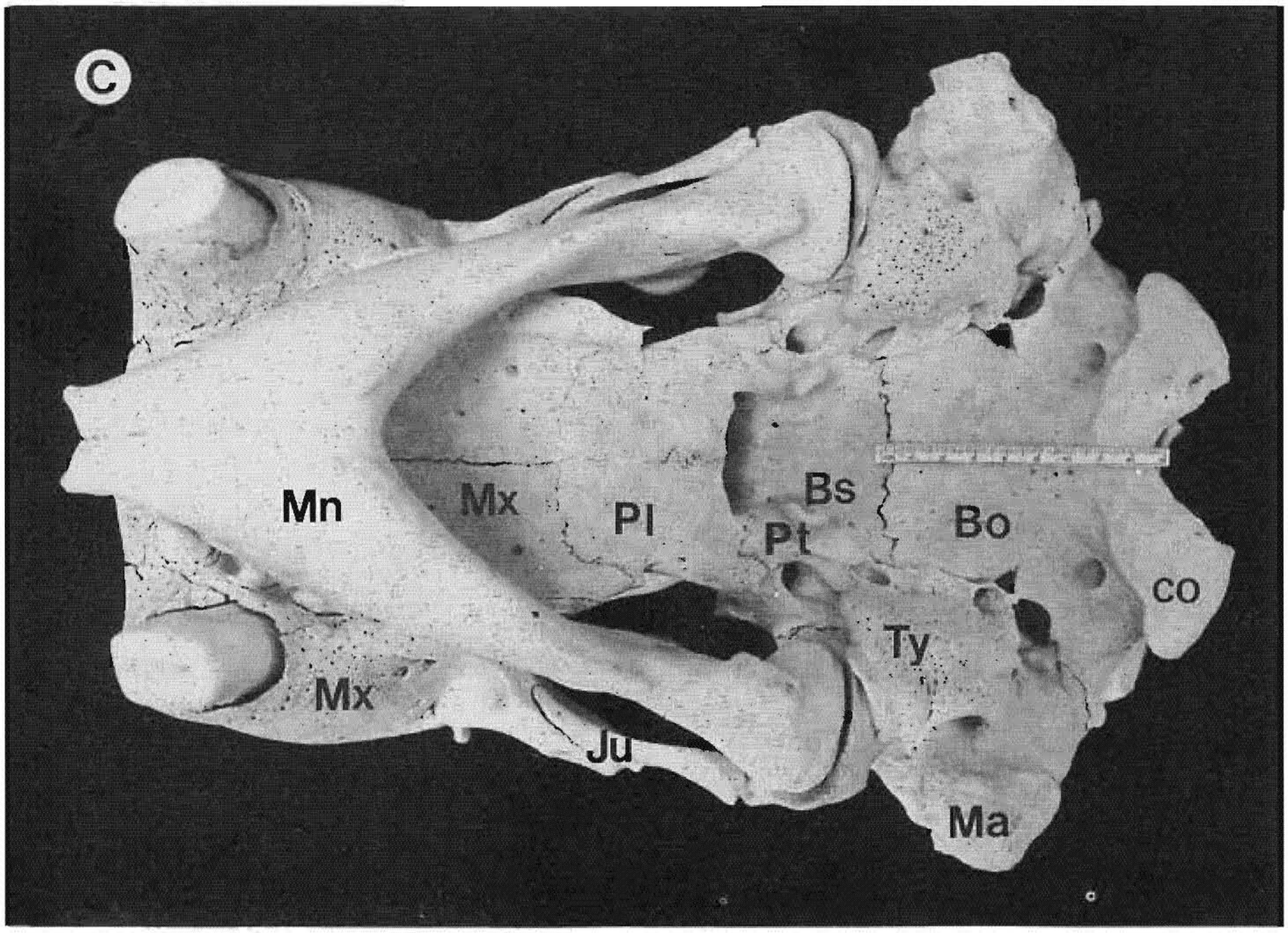

Figure 5. Ventral view of the skulls of: an Atlantic Walrus foetus (A), a 14-month-old male Pacific Walrus (B), a 6-year-old male Pacific Walrus (C), and a 30+-year-old male Pacific Walrus (D). Bones: Mx = Maxilla; Ju = Jugal; Pl = Palatine; Pt = Pterygoid; Bo = Basioccipital; Bs; Basisphenoid;

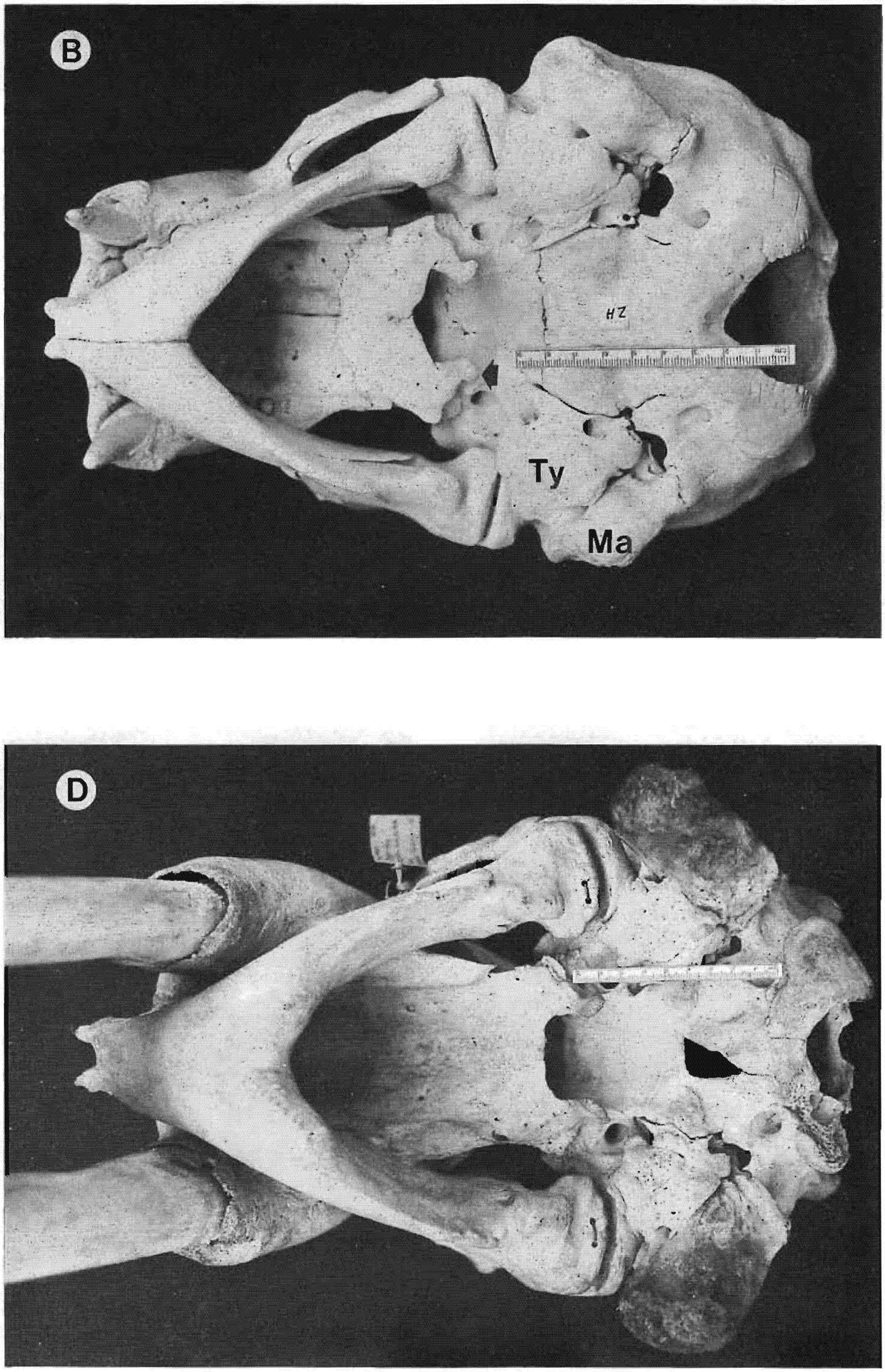

Ty = Tympanic; Ma = Mastoid; Mn = Mandible; co = condylar occipitalis. The arrow indicates the hamulus pterygoideus.

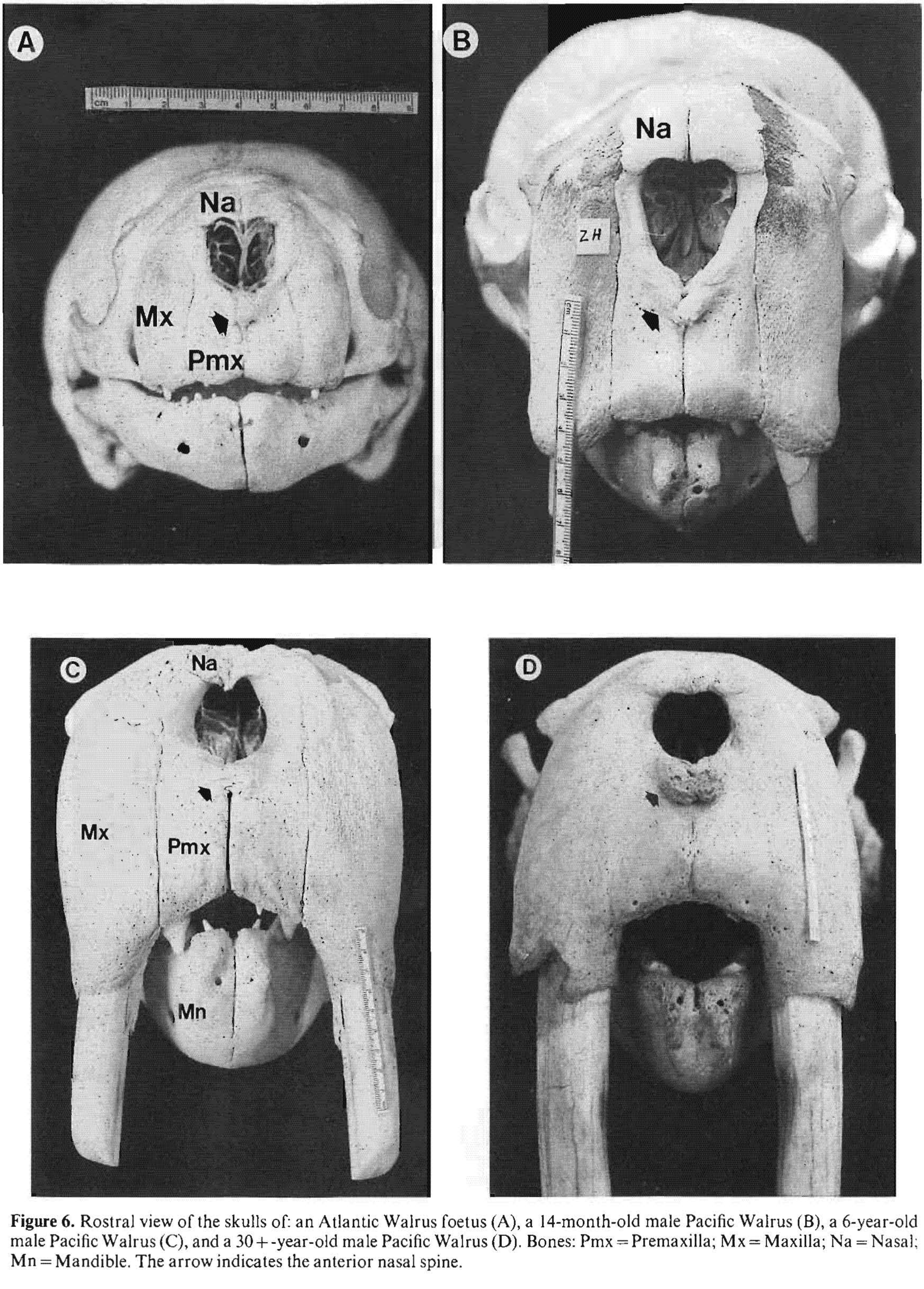

Figure 6. Rostral view of the skulls of: an Atlantic Walrus foetus (A), a 14-month-old male Pacific Walrus (B), a 6-year-old male Pacific Walrus (C), and a 30+-year-old male Pacific Walrus (D). Bones: Pmx = Premaxilla; Mx = Maxilla; Na = Nasal; Mn = Mandible. The arrow indicates the anterior nasal spine.

maxillary artery reaches the infratemporal region. The sphenoid penetrates rostrally in the medial wall of the deep retro-orbital fossa, enclosing the optic canal. Caudally this fossa opens in the very large oval-shaped rotund foramen. Laterally the retro-orbital region is more or less separated from the infra-orbital fossa by a ridge of the sphenoid (Fig. 10).

Mandible: The mandible is exceptionally solid, and from an early age the 2 sides are firmly fused over the rostral one third of its length. The mandible has a very low ramus with a broad coronoid process and a condilar process protruding at the caudal end. There are no teeth in the rostral tip of the mandible (Figs 3c, 4c, 5c, 6c and 9).

3. Cerebral skull

The neurocranium serves to accommodate the large brain (Turner, 1888; Fish, 1903) and as an attachment site for the strong axial musculature.

Parietal: The parietal bones are relatively large and protrude rostrally over the frontals, creating a peculiarly shaped coronal fissure (Figs 3c and 4c).

Temporal: The mastoid processes are strongly developed and deep compared to other pinnipeds. They are responsible for the very broad and flat caudal aspect of the skull. The zygomatic process is separated from the jugal bone by a 2–3 mm wide fissure filled with the zygomatic cartilage. The squamosal part of the temporal is well developed. The triangular tympanic bullae are flattened, and wedged between the mastoid and the condylar fossa of the temporal (Figs 3c, 4c, 5c and 7c).

Occipital: The exoccipital is separated from the mastoid by a prominent suture. Exoccipital and supraoccipital are well fused and participate, together with the parietals, in a supra-occipital crest. The basi-occipital is short and broad, almost square. It is clearly separated from the tympanic by a fissured carotid canal, and from the jugular foramen which shows clearly separated nervous and vascular compartments. The ventral and dorsal condyloid fossae contain large vascular foramina. In the ventral fossa the hypoglossal canal merges into the vascular foramina (Figs 4c, 5c and 7c).

Age related changes

Age related changes were studied in a set of skulls comprising a foetus, a 14-month-old male, a 6-year-old male, and a 30 + -year-old male (Table 1). During maturation the following bones change their original appearance disproportionally:

—The maxillae enlarge due to the strong increase in size and weight of the tusks, making the rostral part of the skull higher from a lateral or rostral view (Fig. 3; see also Fay (1982) page 106), more rectangular from a dorsal and ventral view (Figs 4 and 5) and widening the skull from a frontal view (Fig. 6).

—The mastoid process of the temporal bone enlarges through time laterally and vertrally, making the caudal aspect of the skull broader and more triangular and causing the pivotal line through the occipital condyles to move dorsally (Figs 5 and 7).

—The supra-occipital crest enlarges with age (Figs 3, 4 and 7).

—The occipital condyles enlarge very strongly with age (Figs 3, 5 and 7).

—The rostral ankylosed part of the mandible becomes relatively longer through time (Figs 5, 8 and 9) and from a lateral view, the mandible becomes more curved (Figs 3, 8 and 9).

—The suture between the zygomatic process of the temporal bones and jugal bones is persistent, and was still filled with cartilage in a 15-year-old male Pacific Walrus (OrZH001). In may skulls labelled as 'adults' in which all other sutures were ankylosed, this zygomatic suture was still open (Fig. 3).

Discussion and conclusions

Mechanical adaptations for hauling out

Two important mechanical functions of Walrus tusks are to aid in hauling out onto land or ice (*Odobenus rosmarus* means 'tooth walking sea horse'), and to work as a chisel to keep holes in the ice open (Fay, 1982). These two functions of the tusks could explain the fact that females have tusks as well as males (Fay, 1990). Belcher (1885) described a Walrus hauling itself out of the water onto an ice-floe (Fig. 1): 'It then dug its tusks with a terrific force into the ice that I feared for its brain. Leech-like, the animal hauled itself forward by the enormous muscular power of the neck, repeating the operation until it was secure. The force with which the tusks were struck into the ice appeared not only sufficient to break them, but the concussion was so heavy that I was surprised that any brain could bear it'.

From the outside, the Walrus head looks very solid. The skull consists rostrally of well developed nasal and maxilla bones and caudally of a thick braincase. However, these parts are connected centrally by a thin region consisting of frontal bones, the sphenoid and the palate, and laterally by the zygomatic arches. In transverse sections through the head, the relative development of bones in rostral, intermediate and caudal regions is clearly visible (Fig. 11). The apparent flexibility of this narrow bony connection and the surrounding muscles could reduce the transmission of shocks from the rostal part of the skull towards the braincase. The zygomatic cartilage between the jugal bone and the zygomatic process of the temporal bone is also well suited to reduce the conduction of shocks and vibrations (Fig. 3). This cartilage makes the zygomatic arch flexible and allows lateral and torsional movements between the viscero- and the

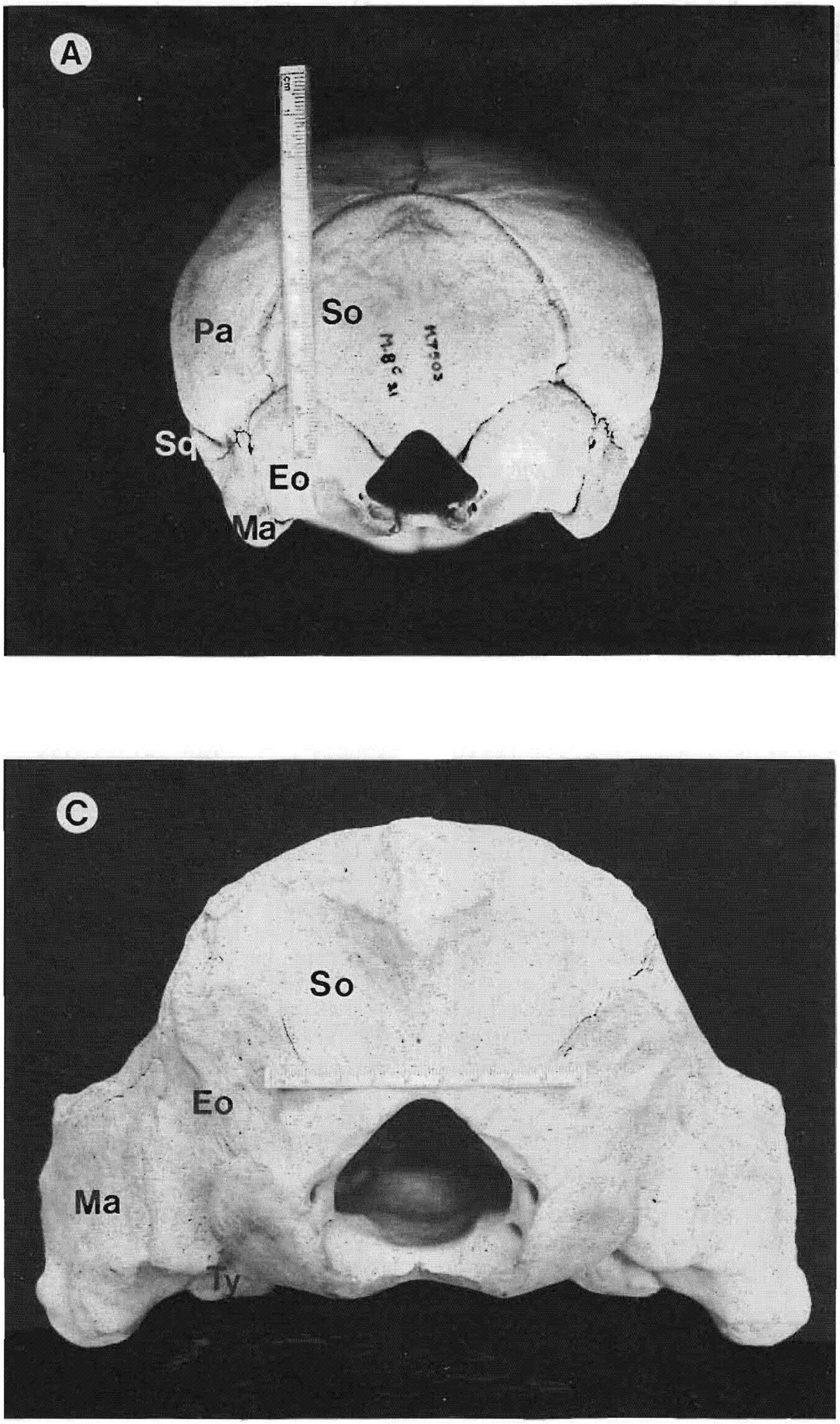

Figure 7. Caudal view of the skulls of: an Atlantic Walrus foetus (A), a 14-month-old male Pacific Walrus (B), a 6-year-old male Pacific Walrus (C), and a 30+-year-old male Pacific

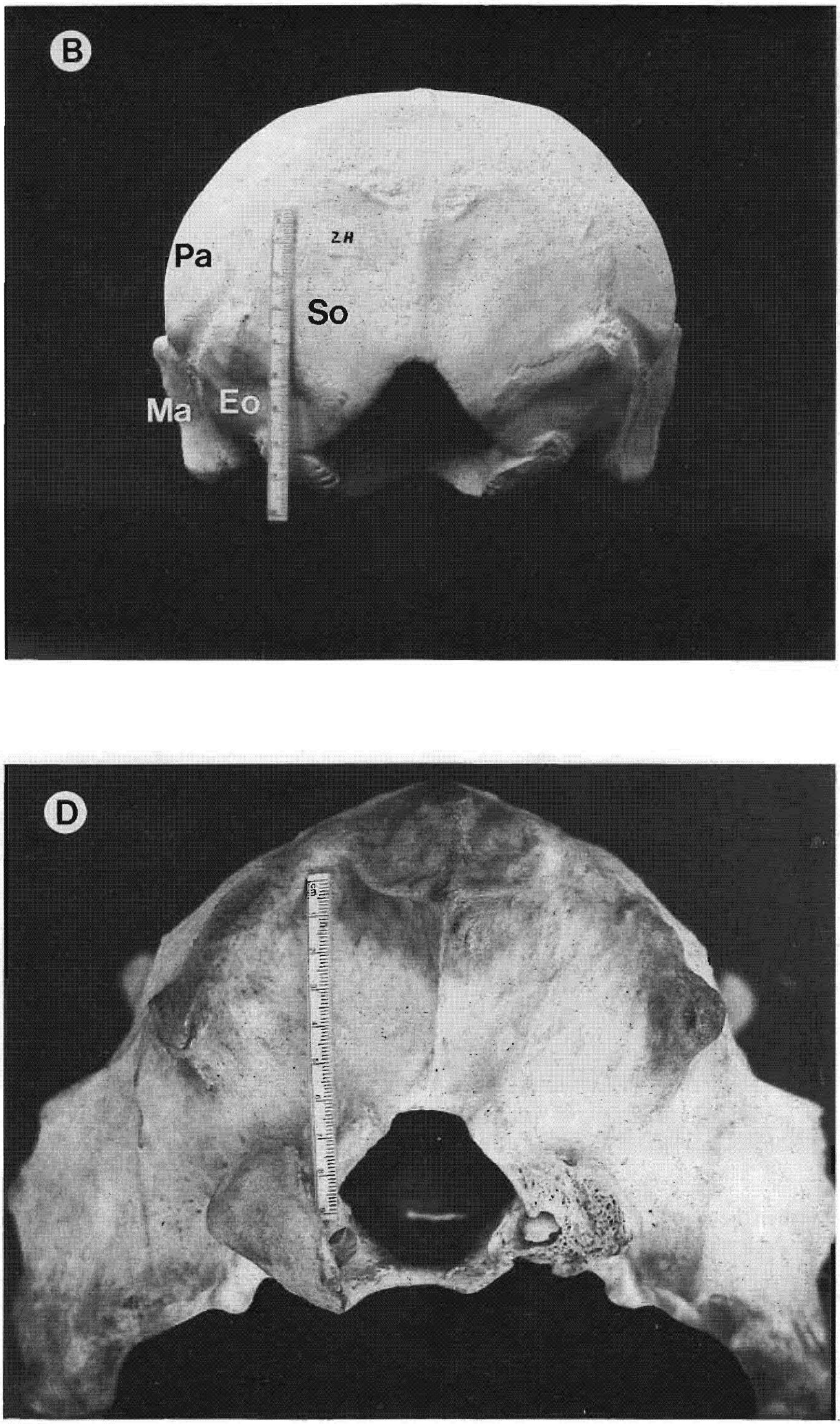

Walrus (D). Bones: So = Supraoccipital; Eo = Exoccipital; Ty = Tympanic; Ma = Mastoid; Pa = Parietal; Sq = Squamosal.

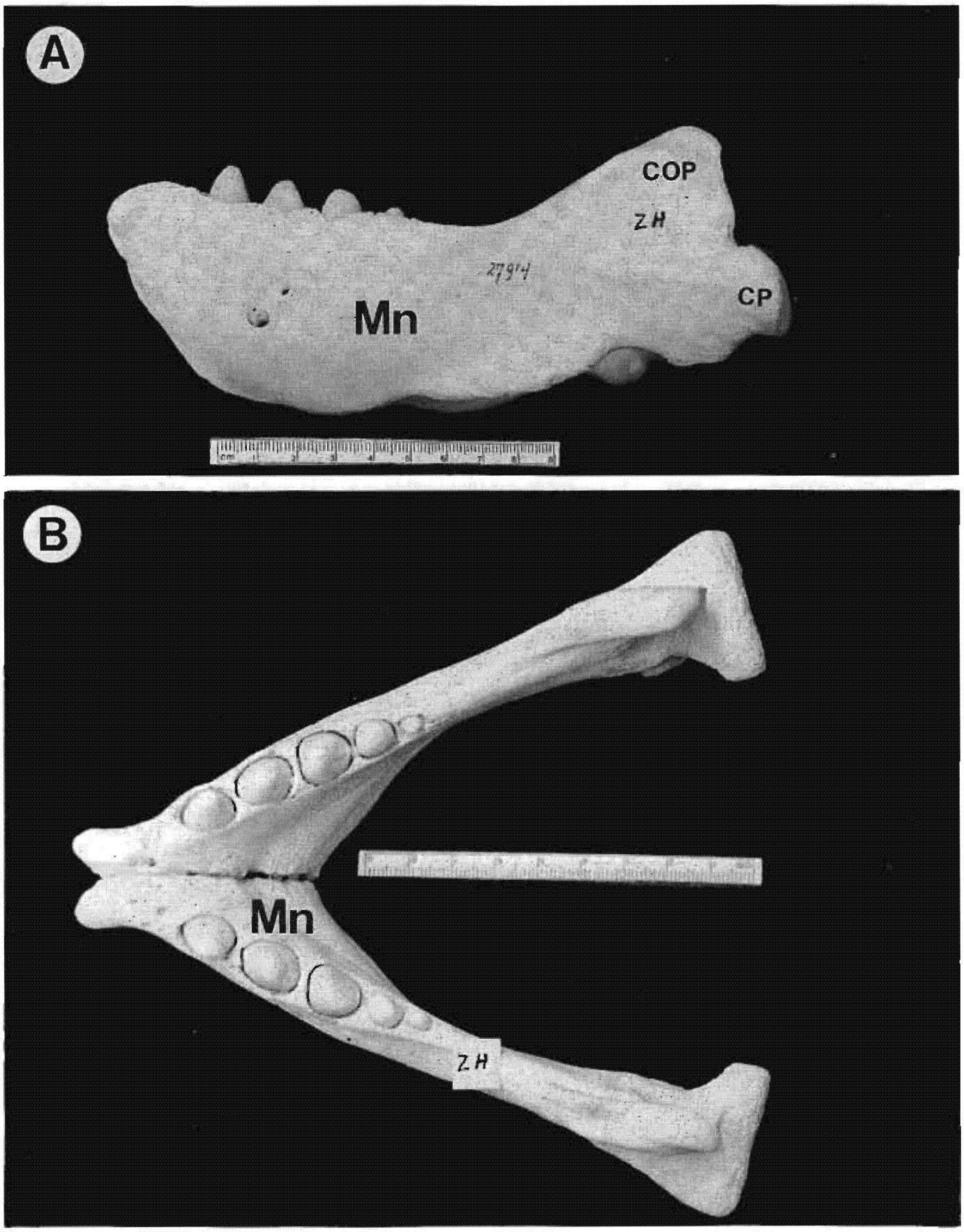

Figure 8. Lateral (A) and Dorsal (B) view of the mandible (Mn) of a 14-month-old male Pacific Walrus (OrZH008). cop = coronoid process; cp = condylar process.

neurocranium when the animal is using its tusks. The tight occlusion which results in the typical pits in the occlusal facets of the cheek teeth (Cobb, 1933; Fay, 1982) may aid also in the deflection of forces originating in the rostral part of the skull. The lower jaw, together with the masticatory and facial muscles, does not nullify the alleged flexibility of the skull, but probably does restrict the movement between the neuro- and viscerocranium.

The fissure between the premaxilla of the 6-year-old animal is still extremely wide, and extends between the palatine processes, with only a small ankylosis at the anterior nasal spine (Fig. 6a, b and c). This would prevent the transmission of torsional forces across the midline when the tusks hit a substrate with inequal impact. This construction may be comparable with the flexibility induced in the pelvis by the fibrous cartilage of the symphysis pubis.

The skull does not only have to withstand blows when the tusks hit the substrate, but it also has to withstand the tractive force produced from the tusks when they act as levers. The tusks can be up to 100 cm

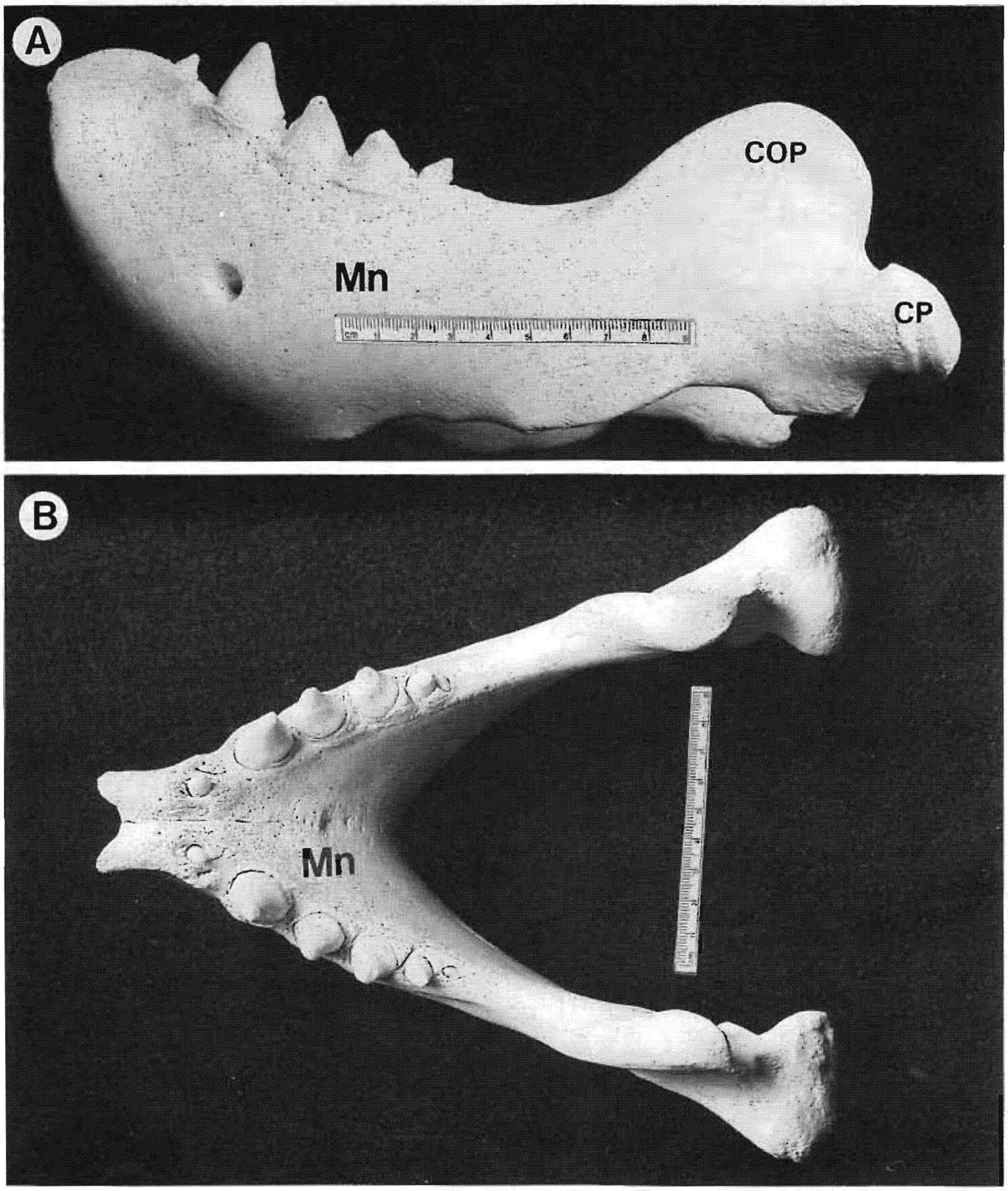

Figure 9. Lateral (A) and Dorsal (B) view of the mandible (Mn) of a 6-year-old male Pacific Walrus (OrZH005). Note the shape of the rostal tip of the jaw, which acts as an attachment substrate for the muscular lower lip. cop = coronoid process; cp = condylar process.

long (Fay, 1982). A considerable surface for attachment of neck flexor muscles is available well below the pivoting line through the occipital condyles, in the form of the deep and ventralward protruding mastoid process (Fig. 7c and d). The supraoccipital crest serves as an attachment site for the strong neck extensor muscles which are needed because the centre of gravity of the Walrus head is located relatively far towards the rostrum. The well developed tusks, premaxillae, maxillae and lower jaw make the rostral part of the head extremely heavy. This could either aid in making a grip on the substate when the animal is hauling out, or in driving the tusks into the ice. The neck muscles are strong enough to enable Walruses to move stones, weighing more than 50 kg, across the floor of a pool (Kastelein & Wiepkema, 1989). Although the neck muscles of the Walrus are immense, the animal is able to make fast and precise head movements (Kastelein *et al.*, 1990).

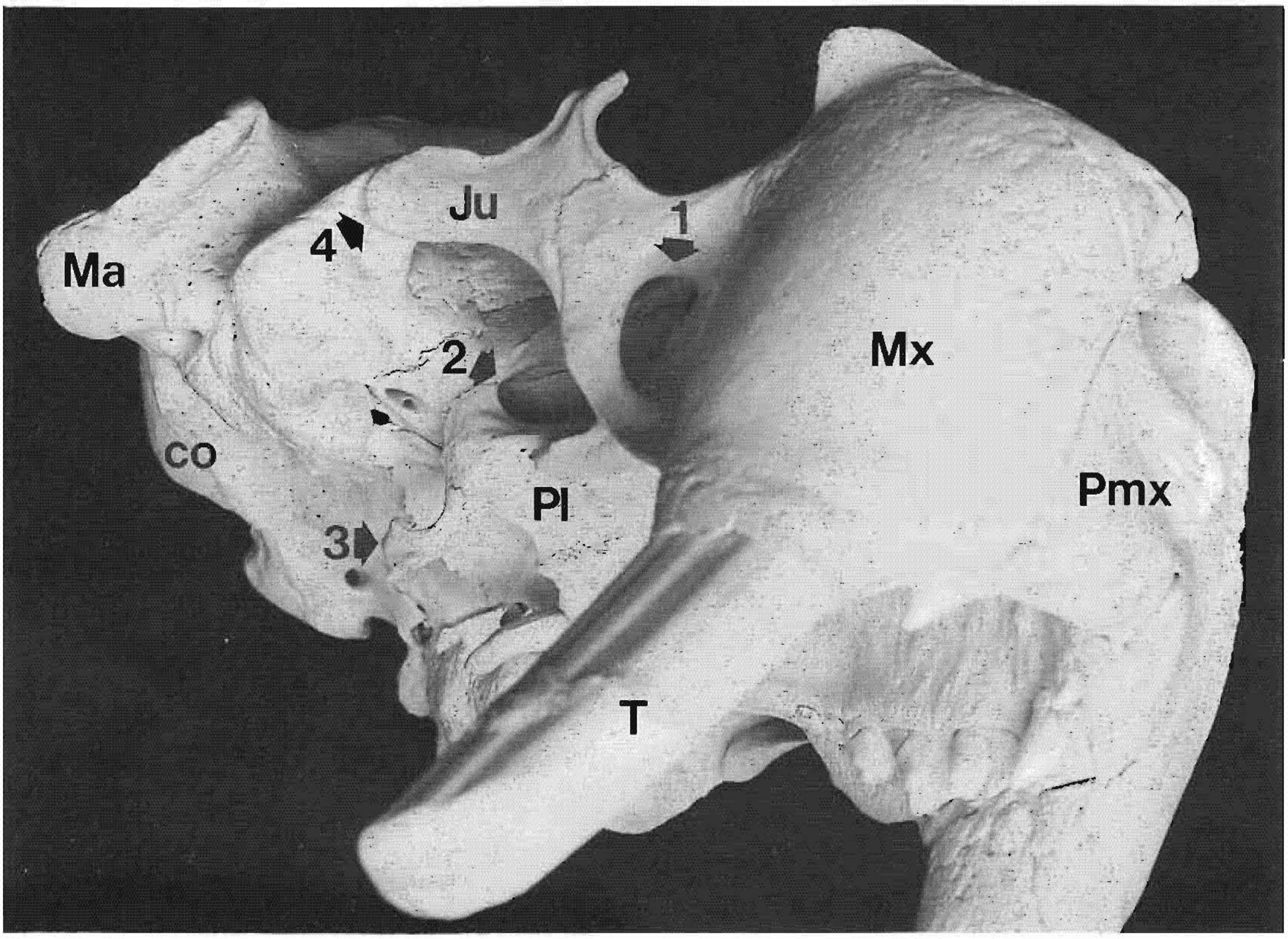

Figure 10. An oblique frontal view of the skull of a 6-year-old male Pacific Walrus. Note the boat shaped roof of the mouth cavity. Arrow 1 indicates the infra-orbital foramen. Arrow 2 indicates the foramen rotundum. Arrow 3 indicates the hamulus pterygoideus. Arrow 4 indicates the zygomatic fissure which, in life, is filled with cartilage. Mx = Maxilla; Pmx = Premaxilla; Ju = Jugal; Ma = Mastoid; Pl = Palatine; T = tusk; co = condylar occipitalis.

Mechanical adaptations for feeding

A Walrus can create large pressure changes in its buccal cavity, and does so when water jetting to excavate bentic prey (Oliver *et al.*, 1983; Kastelein & Mosterd, 1989; Kastelein *et al.*, 1991). After a bivalve mollusc is found, the Walrus sucks the contents from it by creating a highly negative pressure (up to −76 cm Hg) in its mouth, while retracting and depressing the tongue which acts as a piston (Fay, 1982). For both behaviours a tight occlusion is necessary which could explain the typical pitted indentations in occlusal facets of the teeth. The oblique wear found on the lingual facets of the cheek teeth of wild animals is probably not caused by crushing the shells of molluscs, but could be due to the grinding and polishing force of sand when the tongue is moved back and forth in the mouth cavity while excavating bentic prey and in sucking the contents from bivalve molluscs (Fay, 1982).

Walruses have a very large buccal cavity compared to other pinnipeds, which allows for large volume and pressure changes. The palatine process of the maxilla is very arched which was noted by Murie (1871) who called it boat-shaped. Seemingly as an adaptation to the large pressure changes, the internal choana are relatively narrow and only a short soft palate is required to close the nasopharynx. The hamuli of the pterygoid are unusually elongated and curved, reflecting the strong development of the palatine musculature (i.c. *musculus tensor veli palatini*), which can withstand large pressure differences between the nasopharynx and the mouth cavity.

The mandible of the Walrus is extremely heavy, which at first seems unnecessary for an animal that eats such small non-motile bentic prey. Water jetting and suction requires no movement of the jaw at all, but a strong occlusion. Fay (1982) shows the orientation of the trabeculae, and the mechanics of the mandible, indicating that the maximum occlusive force is on its anterior end. This strong occlusive force excerted on the teeth may induce the strong development of the tooth-bearing part of the mandible. Murie (1871) indicated the lack of teeth on the rostral tip of the mandible. The protruding tip of each mandibular half is as an attachment for the large and muscular lower lip which could serve, together with the strongly developed upper lip, to manipulate objects.

Accommodation of the sensory organs
In contrast to other pinnipeds, which have an elongated snout with vibrissae pointing in the caudo-lateral direction, Walruses have a very large, frontally compressed muzzle with vibrissae pointing forwards (Ling, 1977; Yablokov & Klevezal, 1962). Walruses plough in the substrate with their snout and use the vibrissae to identify objects (Fay, 1982; Oliver *et al.*, 1983 & 1985; Kastelein & van Gaalen, 1988; Kastelein *et al.*, 1989; Kastelein & Mosterd, 1989). The premaxillae and maxillae form a flat substrate to which the muzzle and upper lip are attached. The sensory innervation of the muzzle is by the maxillary portion of the trigeminal nerve. As a consequence, the infraorbital foramen of the zygomatic process of the maxilla and the rotund foramen (Fig. 10) are very large (Fay, 1982; Kastelein *et al.*, 1990).

The orbital perimeter is enclosed for two thirds of its circumference by bony structures and is open only at the dorsal side. These structures serve as a substrate for the well developed *orbicularis oculi* muscles that close the eyelids and protect the eye. The Walrus has no supraorbital processes, but the postorbital process of the jugalar bone is strongly developed. For protection, the eyes can probably be retracted into the orbital cavity.

Acknowledgements

We thank Rob Stewart and Kathy Fisher of the Freshwater Institute, Winnipeg, Canada, for the preservation and transport of the Pacific Walrus head. We thank Henk Mosterd and Kees Entius for their technical assistance. The photographs were taken by Henk Merjenburgh and the first author. We thank Evert de Graaf of the Veterinary Department of the University of Utrecht, Holland, and the Natural History Museum of Leiden, Holland, for the use of the Walrus skulls. We also thank the Museum of Zoology in Cambridge, UK, for the use of the Walrus skulls in their collection and Mr M. J. Ashby for his help with the photography. We thank Prof. Dr Jaap Dubbeldam of the Neurobehavioural morphology group of Leiden University and Nancy Vaughan for their comments on the manuscript.

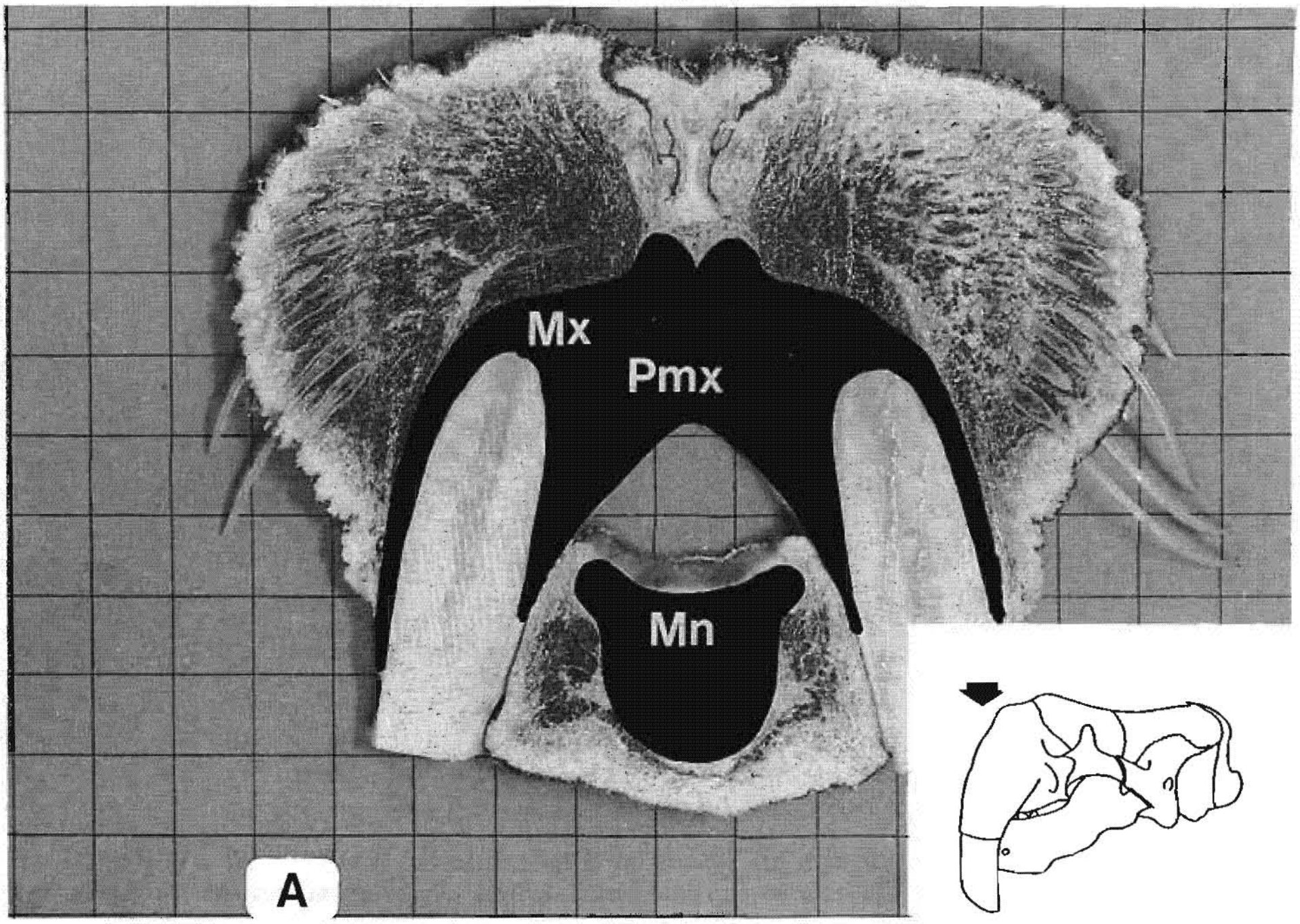

Figure 11. For caption see p. 118.

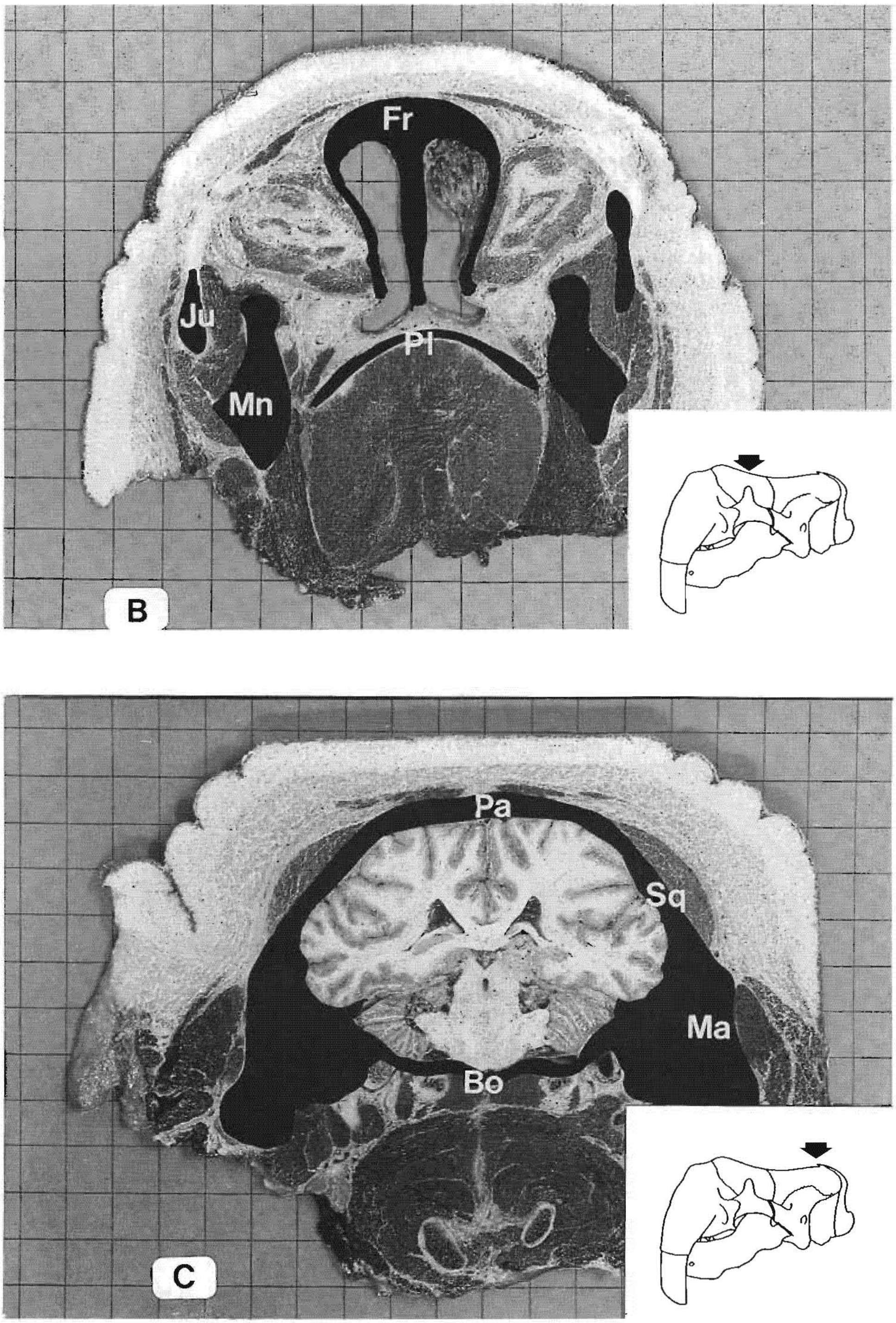

Figure 11. Transverse sections through an 8-year-old female Atlantic Walrus head: (A) Rostral, (B) Intermediate and (C) Caudal. The arrows indicate the locations of the cross-sections. Bony tissue is coloured black. Bones: Pmx = Premaxilla; Mx = Maxilla; Fr = Frontal; Pl = Palatine; Pa = Parietal; Bo = Basioccipital; Sq = Squamosal; Ju = Jugal; Ma = Mastoid; Mn = Mandible. Background grid: 2 × 2 cm.

References

Allan, J. A. (1880) History of North American pinnipeds, a monograph of the walruses, sea-lions, sea bears and seals of North America. US Geol. Geogr. Surv. Terr., Misc. Publ. 12, pp. 785.

Belcher, E. (1885) Last of the Arctic Voyages.

Bosscha Erdbrink, D. P. & van Bree, P. J. H. (1986) Fossil Odobenidae in some Dutch collections (Mammalia, Carnivora). *Beaufortia* **36(2),** 13–33.

Cobb, W. M. (1933) The dentition of the Walrus, *Odobenus obesus*. *Proc. Zool. Soc. (London)*, 645–668.

Fay, F. H. (1981) Walrus *Odobenus rosmarus* (Linnaeus, 1758). In: S. H. Ridgway & R. J. Harrison (eds), Handbook of Marine Mammals. Academic Press, London, 1–23.

Fay, F. H. (1982) Ecology and biology of the Pacific Walrus, *Odobenus rosmarus divergens*, Illiger, North American Faune, 74. Washington, D.C.

Fay, F. H. (1990) Personal communication. Institute of Marine Science, Fairbanks, Alaska.

Fish, P. A. (1903) The cerebral fissures of the Atlantic Walrus. *Proc. US Nat. Mus.* **26,** 675–688.

Fremerij, N. C. de (1831) Bijdragen tot der natuurlijke Geschiedenis van der Walrus (*Trichechus rosmarus* Linn.), en de Kennis der Verscheidenheden, welke onder deze Dierenvoorkomen. *Bijdragen tot de Natuurkundige Wetenschappen* **6,** 360–392.

Kastelein, R. A. & van Gaalen, M. A. (1988) The sensitivity of the vibrissae of a Pacific Walrus (*Odobenus rosmarus divergens*) Part 1. *Aquatic Mammals* **14(3),** 123–133.

Kastelein, R. A., Wiepkema, P. R. & Slegtenhorst, C. (1989) The use of molluscs to occupy Pacific Walruses (*Odobenus rosmarus divergens*) in human care. *Aquatic Mammals* **15(1),** 6–8.

Kastelein, R. A. & Wiepkema, P. R. (1989) A digging trough as occupational therapy for Pacific Walruses (*Odobenus rosmarus divergens*) in human care. *Aquatic Mammals* **15(1),** 9–17.

Kastelein, R. A. & Mosterd, P. (1989) The excavation technique for molluscs of Pacific Walruses (*Odobenus rosmarus divergens*) under controlled conditions. *Aquatic Mammals* **15(1),** 3–5.

Kastelein, R. A., Stevens, S. & Mosterd, P. (1990) The tactile sensitivity of the mystacial vibrissae of a Pacific Walrus (*Odobenus rosmarus divergens*) Part 2: Masking. *Aquatic Mammals* **16(2),** 78–87.

Kastelein, R. A., Paasse, M., Klinkhamer, P. & Wiepkema, P. R. (1991) Food dispensers as occupational therapy for Walruses (*Odobenus rosmarus*) in human care. *Int. Zoo. Yearb.* **30**.

King, J. E. (1964) Seals of the World. Trustees of the British Natural History Museum, London, 37–42.

Ling, J. K. (1977) Vibrissae of marine mammals. In: R. J. Harrison (ed.), Functional anatomy of marine mammals. Academic Press, 387–416.

Mohr, E. (1942) Geschlechtsunterschiede am Walroß-Schädel. *Zoologischer Anzeiger* **137(5/6),** 71–76.

Murie, J. (1871) Researches upon the anatomy of Pinnipedia. Part 1. On the Walrus (*Trichechus rosmarus*, Linn.). *Trans. Zool. Soc. (London)* **7,** 411–464.

Oliver, J. S., Slattery, P. N., O'Connor, E. F. & Lowry, L. F. (1983) Walrus, *Odobenus rosmarus*, feeding in Bering Sea: a bentic perspective. *Fisheries Bull.* **81(3),** 501–512.

Oliver, J. S., Kvitek, R. G. & Slattery, P. N. (1985) Walrus feeding disturbances: scavenging habits and recolonization of the Bering Sea benthos. *J. Exp. Mar. Biol. Ecol.* **91,** 233–246.

Repenning, C. A. & Tedford, R. H. (1977) Otarioid Seals of the Neogene. Prof. Paper 992. U.S. Geol. Survey, Washington.

Turner, W. (1888) Report on the seals. Zoology of the voyage of H.M.S. Challenger. 26(68).

Yablokov, A. V. & Klevezal, G. A. (1962) Whiskers of whales and seals and their distribution, structure and significance. In: S. E. Kleinenberg (ed.), Morphological characteristics of aquatic mammals. Nauka, Moskow, 48–81.